

# Renal Involvement in Collagen Vascular Diseases and Dysproteinemias

*Jo H.M. Berden*  
*Karel J.M. Assmann*

**R**enal involvement in systemic lupus erythematosus (SLE), dysproteinemias, and certain rheumatic diseases, namely rheumatoid arthritis, Sjögren's syndrome, and scleroderma (systemic sclerosis), is discussed. SLE is a systemic autoimmune disease that can lead to disease manifestations in almost every organ. SLE is characterized by the formation of a wide array of autoantibodies mainly directed against nuclear autoantigens, of which antibodies against double-stranded DNA (dsDNA) are the most prominent. Although the cause is still obscure, considerable progress has been made recently by identification of the nucleosome as the major driving autoantigen in SLE and the possible role of disturbances in apoptosis in disease development. The section on SLE reviews the major clinical and serologic features of the disease, the serologic analysis, new insights into the pathophysiology of lupus nephritis, and the histologic assessment of kidney biopsies. The therapeutic options for treatment of lupus nephritis are discussed as are the results of treatment of end-stage renal disease in patients with SLE.

The second part of this chapter deals with the renal involvement in dysproteinemias. The renal lesions of these diseases, characterized by an overproduction of abnormal immunoglobulins or their subunits, are quite heterogeneous. Because the kidney often is affected in these disorders, it is not unusual for examination of a kidney biopsy specimen to reveal clues for the diagnosis. On immunofluorescence, the distribution of the light or heavy chain isotype, or both, can be detected in the tissue deposits, whereas electron microscopy can define the ultrastructural organization. Incidence and types of renal involvement, the pathogenesis and risk factors for the various types of renal lesions, the histology of the different renal manifestations, and an

CHAPTER

11

overview of the therapy are given. The renal manifestations of cryoglobulinemias and fibrillary and immunotactoid glomerulonephritis also are discussed.

The third part of this chapter presents a concise review of renal involvement in rheumatoid arthritis, Sjögren's syndrome, and scleroderma.

## Systemic Lupus Erythematosus

### CUMULATIVE INCIDENCE OF CLINICAL SYMPTOMS AND AUTOANTIBODY FORMATION IN SYSTEMIC LUPUS ERYTHEMATOSUS

	Percent
Frequency of major clinical symptoms	
Musculoarticular symptoms	60–95
Cutaneous manifestations	55–80
Renal involvement	40–55
Neuropsychiatric disease	30–60
Pulmonary and cardiac disease	20–40
Hematologic abnormalities	60–85
Occurrence of major autoantibody specificities	
Antinuclear autoantibody	95
Anti-double-stranded DNA	60–75
Antihistone	50–70
Antinucleosome	Up to 80
Anti-Sm	10–30
Anti-ribonucleoprotein (RNP)	10–30
Anti-Sjögren's syndrome (SS-A) (Ro)	20–60
Anti-SS-B (La)	15–40
Anticardiolipin	10–30
Antierythrocyte	50–60
Antilymphocyte	50–70
Antiplatelet	10–30

**FIGURE 11-1**

This overview of the major clinical symptoms illustrates the systemic character of lupus erythematosus. Depending on patient selection, renal involvement occurs in up to half of patients. In almost all patients, antibodies are formed against nuclear antigens, as detected by antinuclear antibody (ANA) testing. These ANAs are either directed against nucleic acids (DNA), nuclear proteins (histones, Sm, ribonucleoprotein, Sjögren's syndrome-A [SS-A], and SS-B) or nucleosomes that consist of DNA and the DNA binding proteins histones. In addition, antibodies can be formed against the anionic phospholipid cardiolipin. This latter antibody specificity is characteristic for the antiphospholipid syndrome either primary or secondary to systemic lupus erythematosus. All these antigens recognized by lupus autoantibodies share the property that they are present in apoptotic blebs at the surface of cells undergoing apoptosis. In addition to these ANAs, autoantibodies against blood cells frequently develop in lupus, giving rise to hemolytic anemia positive on Coombs testing, lymphopenia, or thrombopenia.

### EPIDEMIOLOGIC AND GENETIC CHARACTERISTICS OF SYSTEMIC LUPUS ERYTHEMATOSUS

Epidemiology	Genetics
Prevalence: between 25 and 250 per 100,000 persons, depending on racial and geographic background	Concordancy in twins Monozygotic: 50–60% Dizygotic: 5–10%
Race: more prevalent in Asians and blacks	Familial aggregation in 10%
Gender: female preponderance; gender ratio between 20 and 40 years; male:female, 1:9	Association with the following: HLA: B7, B8, DR2, DR3, DQ <sub>w</sub> 1
Age: onset mainly between 20–40 y	Complement: C4A Q0 C1q or C4 deficiency Fc $\gamma$ receptor IIA low-affinity phenotype X chromosome ?

**FIGURE 11-2**

The major epidemiologic characteristics of systemic lupus erythematosus are listed. The prevalence of the disease depends on ethnic background. The highest prevalence is seen in Asians and Blacks. As in other systemic autoimmune diseases, there is a striking preponderance in women, especially during childbearing age. This preponderance is related to hormonal status. Animal studies have shown that estrogens have a facilitating effect on disease expression, whereas androgens have a suppressive effect. The importance of estrogens is further substantiated by the fact that changes in the hormonal homeostasis (*eg*, at onset of puberty, during use of oral contraceptives, and during pregnancy and puerperium) are associated with an increased frequency of lupus onset and disease flare-up. The genetic susceptibility is illustrated by the concordance of the disease in twins, occurrence of familial aggregation, and association with certain genes, mainly human leukocyte antigens (HLA).

### THE 1982 REVISED AMERICAN RHEUMATISM ASSOCIATION CRITERIA FOR CLASSIFICATION OF SYSTEMIC LUPUS ERYTHEMATOSUS

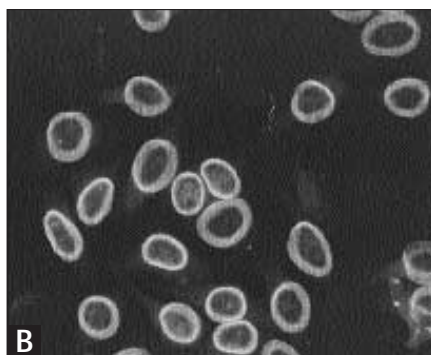
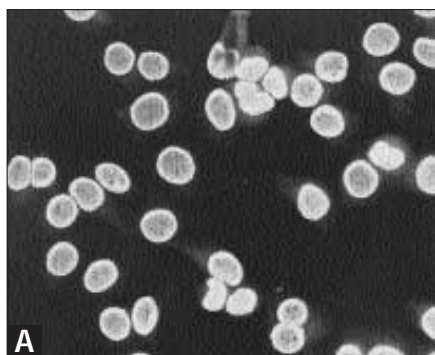
Criterion	Sensitivity, %*	Specificity, %*
1. Malar rash	57	96
2. Discoid rash	18	99
3. Photosensitivity	43	96
4. Oral ulcers	27	96
5. Arthritis (two or more joints)	86	37
6. Serositis: Pleuritis <i>or</i> pericarditis	56	86
7. Renal disorder: Proteinuria > 0.5 g/24 h <i>or</i> cellular casts (red, hemoglobin, granular, tubular, or mixed)	51	94
8. Neurologic disorder: Seizures <i>or</i> psychosis	20	98
9. Hematologic disorder: Hemolytic anemia <i>or</i> leukopenia ( $<4 \times 10^9/L$ ) <i>or</i> lymphopenia ( $<1.5 \times 10^9/L$ ) <i>or</i> thrombopenia ( $<100 \times 10^9/L$ )	59	89
10. Immunologic disorder: Positive LE cell test result <i>or</i> positive anti-double-stranded DNA <i>or</i> positive anti-Sm <i>or</i> false-positive TPI/VDRL test	85	93
11. Antinuclear antibody	99	49

\*The sensitivity was calculated as the percentage of patients with SLE who were positive for this criterion over those in whom this criterion was analyzed. The specificity was calculated as the percentage of the number of patients in the control group who were negative or normal for that criterion over those in whom this criterion was analyzed.

TPI—treponemal immobilization; VDRL—Venereal Disease Research Laboratory.  
Data from Tan *et al.* [1].

**FIGURE 11-3**

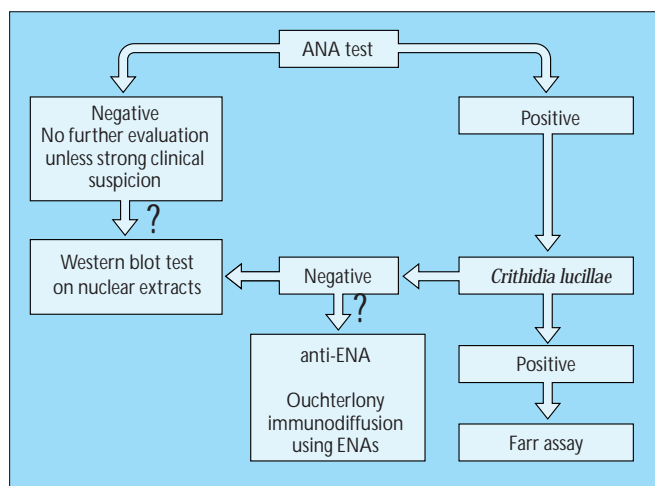
These criteria were selected for their sensitivity and specificity in classifying patients with systemic lupus erythematosus (SLE). In the selection process, these criteria were analyzed in 177 patients with SLE and 162 patients in the control group matched for age, gender, and race. Patients in the control group had a nontraumatic nondegenerative connective tissue disease, mainly rheumatoid arthritis ( $n = 95$ ). The presence of four of these criteria for the diagnosis of SLE has a sensitivity of 96% and specificity of 96% in patients with SLE. For the purpose of identifying patients in clinical studies, it is determined that a patient has SLE when at least four of these criteria are present, serially or simultaneously, during any interval of observation.



**FIGURE 11-5**

Patterns of antinuclear antibody (ANA) staining. The ANA test is carried out by incubation of the serum with either preparations of cultured cells (eg, human cervical carcinoma cells [HeLa cells]) or sections of normal tissue (mostly liver). Antibodies bound to the nucleus are detected by a fluorescinated anti-human immunoglobulin antibody that can reveal four distinctive staining patterns: **A**, homogeneous; **B**, rim or peripheral;

(Continued on next page)



**FIGURE 11-4**

Algorithm for analysis of antinuclear antibodies (ANA) in systemic lupus erythematosus. To demonstrate the presence of antinuclear antibodies the ANA test is used as a screening procedure. Details of this ANA test and the different ANA patterns are given in Figure 11-5. A positive ANA test result indicates the presence of antinuclear antibodies. Although the pattern of ANA can give an indication about the specificity of the antinuclear antibody, additional tests are needed to define this specificity. Antibody specificity to double-stranded DNA (dsDNA) can be identified by the *Crithidia* assay (Fig. 11-6), in which a single-celled organism is used that has purely dsDNA in the kinetoplast. When this test result is positive, the titer of anti-dsDNA antibodies can be determined using the Farr assay (Fig. 11-7). When these anti-dsDNA test results are negative, ANA positivity is most likely caused by antibodies directed against nuclear proteins. Autoantibodies can be analyzed by the Western blot test on nuclear extracts (Fig. 11-8). The advantage of this technique over the Ouchterlony technique using extractable nuclear antigens (ENA), is that the Western blot test allows identification of a large number of autoantibody specificities in one test, although both tests do not completely overlap.

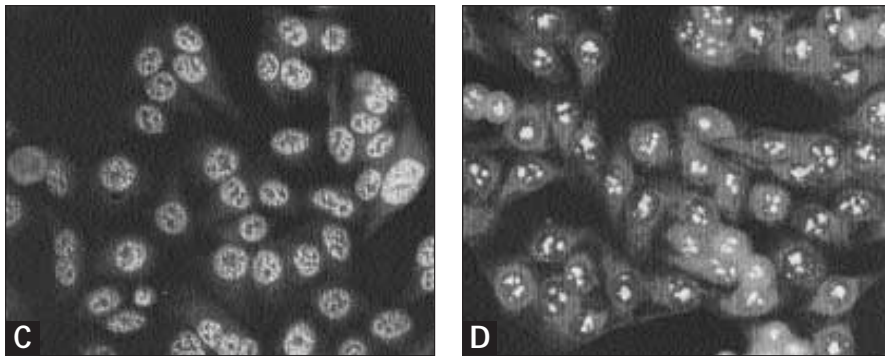


FIGURE 11-5 (Continued)

**C**, speckled; and **D**, nucleolar. Although not conclusive, these patterns can give an indication about the autoantibody specificity causing the nuclear staining. The homogeneous and peripheral patterns mainly are caused by autoantibodies directed against the nucleosome (histone–DNA complex) or double-stranded DNA. The speckled pattern can be observed in antibodies against the nuclear proteins Sm, ribonucleoprotein, Sjögren's syndrome-A [SS-A] (Ro), SS-B (La), Jo-1, topoisomerase I, and anticentromere antibodies. The nucleolar staining is associated with antibodies against nucleolus-specific RNA, as seen in certain limited forms of scleroderma. (From Maddison [2]; with permission.)

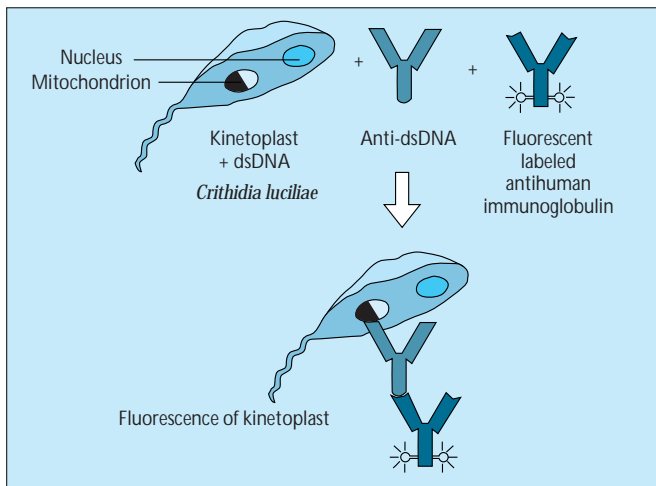


FIGURE 11-6

Screening for anti-doubled-stranded DNA (dsDNA) antibodies using the *Crithidia luciliae* assay. The hemoflagellate *Crithidia luciliae* contains in its kinetoplast pure dsDNA, not complexed to proteins [3]. Serially diluted serum samples are added to the slide carrying *Crithidia* cells. Binding of antibodies is visualized by fluorescinated anti-immunoglobulin G antibodies. Antibodies to dsDNA are almost pathognomonic for systemic lupus erythematosus and therefore can be regarded as marker antibodies [4]. (From Klippel and Croft [5]; with permission.)

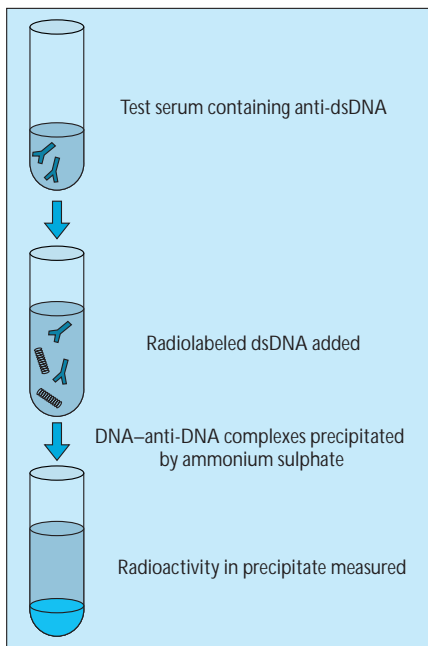
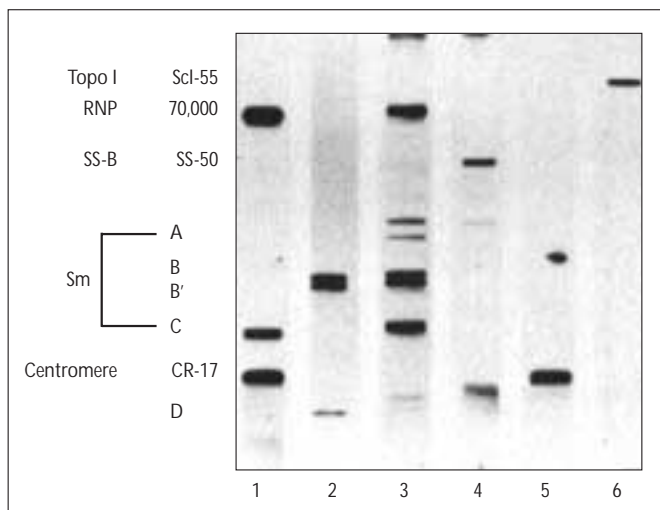


FIGURE 11-7

Farr assay for quantitative measurement of anti-double-stranded DNA (dsDNA) antibodies. The serum to be tested is added to a tube containing radiolabeled dsDNA. When antibodies to dsDNA are present, they bind to the dsDNA. Eventually, formed complexes are precipitated in 50% ammonium sulfate. By testing several dilutions of the serum and comparing them with a standard curve the results can be expressed in units per milliliter. Because high salt conditions are used, this assay detects only high avidity anti-dsDNA antibodies [4]. Positivity and titer in this Farr assay are correlated with renal disease in patients with systemic lupus erythematosus. This titer can be used to monitor lupus disease activity together with complement levels and clinical parameters. In 80% to 90% of cases, disease onset or flare-up is associated with increases in anti-dsDNA titers in the Farr assay [6]. (From Maddison [2]; with permission.)

**FIGURE 11-8**

Western blot test of autoantibodies on nuclear extracts. Nuclear proteins extracted from human cervical carcinoma cells (HeLa cells) are separated on polyacrylamide gel and transferred to nitrocellulose. Subsequently, identical strips of the blot are incubated with various patient sera. Binding of autoantibodies can be visualized with peroxidase or alkaline phosphatase-labeled antihuman immunoglobulin.

Lane 1: anti-ribonucleoprotein (RNP) and centromere (CR-17) activity

Lane 2: anti-Sm (B/B'-D)

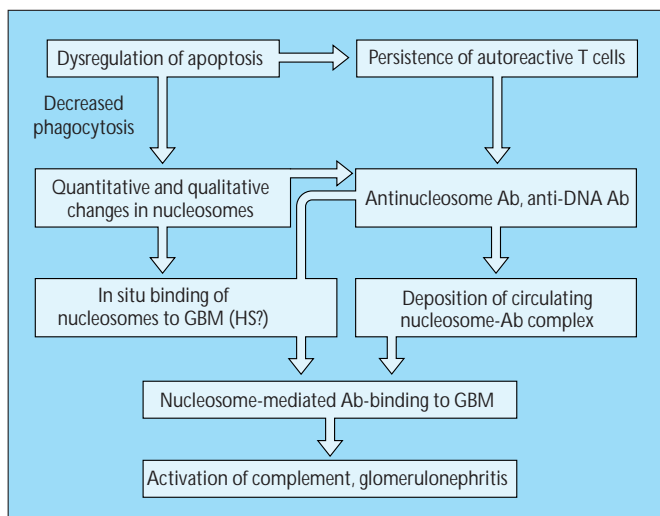
Lane 3: anti-RNP and anti-Sm

Lane 4: anti-Sjögren's syndrome (SS-B) (La)

Lane 5: anticentromere

Lane 6: antitopoisoemerase I (Topo I)

Antibodies against Sm are rather specific for systemic lupus erythematosus (SLE) and can be used as marker antibody, anti-ribonucleoprotein for mixed connective tissue disease (MCTD), centromere (CR17) for the limited variant of scleroderma, SS-B for Sjögren's syndrome and SLE, and topoisomerase I for systemic scleroderma. The Western blot test is a simplified version of the currently available technique, which allows identification of autoantibodies to much more autoantigens. Reference 7 provides a full description of the diagnostic possibilities. (From Van Venrooij *et al.* [8]; with permission.)

**FIGURE 11-9**

Hypothesis for the pathophysiology of lupus nephritis. In recent years, evidence has emerged that the process of apoptosis is disturbed in systemic lupus erythematosus (SLE). The first indication was found in the MRL/l lupus mouse model, in which a deficiency of the Fas receptor was identified [9]. Activation of this Fas receptor induces apoptosis. Transgenic correction of the Fas-receptor defect prevents development of lupus [10]. In human SLE, Fas receptor expression is normal; however, a number of other observations indicate abnormalities in apoptosis [11,12] (Fig. 11-10). Alterations in apoptosis can lead to the persistence of autoreactive T and B cells, because apoptosis is the major mechanism for the elimination of autoreactive cells. In addition, these alterations can lead to quantitative and qualitative differences in the release of nucleosomes (Fig. 11-10).

Nucleosomes are the basic structures of chromatin. They consist of pairs of the core histones H2A, H2B, H3, and H4 around which double-stranded DNA (dsDNA) is wrapped twice. DNA in the circulation

of patients with SLE is present in the form of oligonucleosomes [13]; the only way to generate these oligonucleosomes is by the process of apoptosis. Presently, ample evidence exists that the autoimmune response in SLE is T-cell-dependent and autoantigen-driven [14]. However, dsDNA is very poorly immunogenic, which is in line with the fact that antigen-presenting cells cannot present DNA-derived oligonucleotides to T cells by way of their major histocompatibility complex class II molecules. However, recently it has become evident that the nucleosome is the driving autoantigen in SLE.

In murine lupus, T cells specific for nucleosomes have been identified. These T cells not only drive the formation of nucleosome-specific autoantibodies (*ie*, antibodies that react with the intact nucleosome but not with its constituent DNA and histones) but also the formation of anti-DNA and antihistone antibodies [15]. The histone-derived epitopes that drive these responses recently have been identified [16]. These nucleosome-specific autoantibodies precede the emergence of anti-dsDNA and antihistone antibodies, suggesting that the loss of tolerance for nucleosomes is an initial key event in SLE [17,18]. Both in human and murine lupus, nucleosome-specific antibodies are detected in up to 80% of cases [18–20].

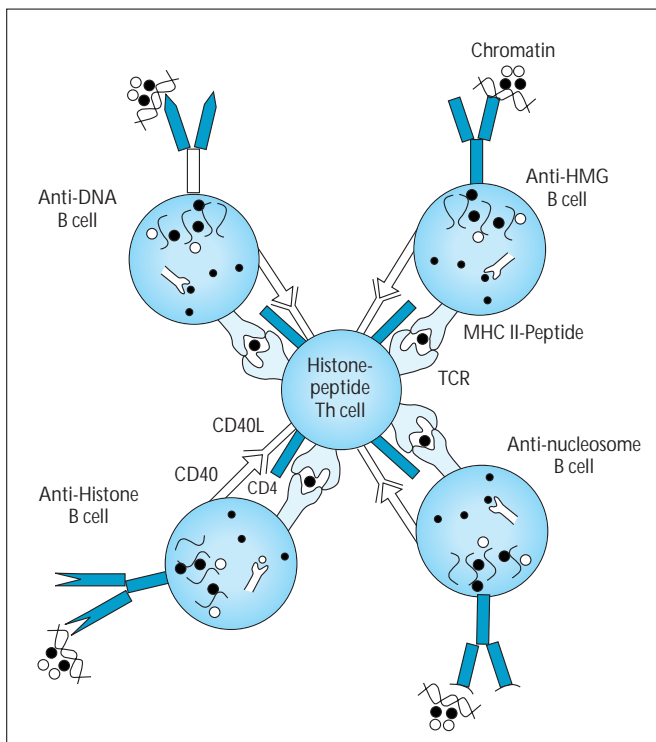
Figure 11-11 illustrates the central role of the nucleosome in the generation of the antinuclear autoantibody repertoire. These antinucleosome and anti-DNA antibodies, after complex formation with the nucleosome, can localize in the glomerular basement membrane (GBM) by way of binding to heparan sulfate (HS). This binding occurs through binding of the cationic histone part of the nucleosome to the anionic HS, as demonstrated by *in vivo* perfusion studies [21]. The relevance of this binding mechanism for lupus nephritis was shown by the elution of nucleosome-specific autoantibodies from glomeruli, identification of nucleosome deposits in glomeruli of patients with lupus nephritis, and presence of nucleosome-antinucleosome antibody complexes in the glomerular capillary wall in patients with lupus nephritis [18,22–25]. The pathophysiologic significance of this nucleosome-mediated binding to the GBM was illustrated by the observation that heparin could prevent this binding and inhibit the glomerular inflammation and proteinuria in lupus mice [26]. References 11 and 14 provide a more detailed description of these mechanisms.

### INDICATIONS FOR A DISTURBED APOPTOSIS IN HUMAN SYSTEMIC LUPUS ERYTHEMATOSUS

Finding	Study
Increased expression of Fas receptor	Mysler <i>et al.</i> [28], Lorenz <i>et al.</i> [29]
Circulating levels of soluble Fas	
Increased	Cheng <i>et al.</i> [30]
Normal	Goel <i>et al.</i> [31], Knipping <i>et al.</i> [32]
Increased <i>in vitro</i> apoptosis of lymphocytes	Lorenz <i>et al.</i> [29], Emlen <i>et al.</i> [33]
Abnormal anti-CD3–induced apoptosis	Kovacs <i>et al.</i> [34]
Apoptosis-induced alterations of autoantigens	
Proteolysis	Casciola-Rosen <i>et al.</i> [35], Casiano <i>et al.</i> [36], Rosen and Casciola-Rosen [37], Casiano [38]
Phosphorylation	Utz <i>et al.</i> [39]
Reactive oxygen species–mediated damage	Cooke <i>et al.</i> [40]
Apoptosis-induced surface expression of autoantigens	Casciola-Rosen <i>et al.</i> [41], Jordan and Kuebler [42]
Decreased phagocytosis of apoptotic cell	Herrmann <i>et al.</i> [43]

**FIGURE 11-10**

On the one hand, indications exist that apoptosis is increased in human systemic lupus erythematosus (SLE) (*eg.* increased Fas expression and increased *in vitro* apoptosis). On the other hand, some findings suggest that apoptosis is decreased (*eg.* increased levels of soluble Fas, increased bcl-2 expression, and decreased anti-CD3–induced apoptosis). Bcl-2 is a physiologic inhibitor of apoptosis, and transgenic induction of bcl-2 overexpression leads to lupuslike autoimmunity [27]. Although presently it is difficult to reconcile these findings, it is clear that changes in the delicate balances governing apoptosis can lead to apoptosis at the wrong moment (too late) or at the wrong place (systemically instead of locally).



**FIGURE 11-11**

Central role of T cells specific for nucleosomal histone peptides in the generation of the antinuclear autoantibody repertoire in systemic lupus erythematosus. The cascade begins with the uptake of nucleosomes by B cells by way of their antigen receptor. After endosomal antigen processing, these B cells present histone peptides to T cells. After activation of the T cell, it provides help to the presenting B cell, leading to the formation of nucleosome-specific autoantibodies. Binding of B cells to other determinants on the nucleosome (B cells specific for DNA, histones, or the nonhistone chromosomal peptides high-mobility group proteins [HMG]) and antigen-processing by these B cells, can generate additional antinuclear autoantibody responses (anti–double-stranded DNA, antihistone, and anti-HMG). This intramolecular antigen-spreading owing to different endosomal antigen-processing revealing cryptic neoepitopes, is now known for a number of autoimmune responses [44]. MHC—major histocompatibility complex; TCR—T-cell receptor. (*From* Datta and Kaliyaperumal [45]; with permission.)

### WORLD HEALTH ORGANIZATION MORPHOLOGIC CLASSIFICATION OF LUPUS NEPHRITIS (1995 REVISED VERSION)

#### Class

- I. Normal glomeruli
  - A. Nil (by all techniques)
  - B. Normal on light microscopy but deposits seen on electron or immunofluorescence microscopy
- II. Pure mesangial alterations (mesangiopathy)
  - A. Mesangial widening, mild hypercellularity, or both
  - B. Moderate hypercellularity
- III. Focal segmental glomerulonephritis (associated with mild or moderate mesangial alterations)
  - A. Active necrotizing lesions
  - B. Active and sclerosing lesions
  - C. Sclerosing lesions
- IV. Diffuse glomerulonephritis (Severe mesangial, endocapillary, or mesangiocapillary proliferation, and/or extensive subendothelial deposits. Mesangial deposits are present invariably and subepithelial deposits often, and may be numerous.)
  - A. Without segmental lesions
  - B. With active necrotizing lesions
  - C. With active and sclerosing lesions
  - D. With sclerosing lesions
- V. Diffuse membranous glomerulonephritis
  - A. Pure membranous glomerulonephritis
  - B. Associated with lesions of category II (A or B)
- VI. Advanced sclerosing glomerulonephritis

**FIGURE 11-12**

The various morphologic manifestations of lupus nephritis are classified in several categories based on criteria formulated in 1974, modified in 1982 and 1995, and designated as the World Health Organization (WHO) classification of lupus nephritis [46,47]. The different forms of glomerulonephritis, as morphologically defined by the WHO classification, also are characterized by typical patterns of deposits of several classes of immunoglobulins and complement factors [48]. Class I lupus nephritis has been defined by normal glomeruli by all techniques, or by normal glomeruli on light microscopy, with minor deposits as seen on immunofluorescence (IF) or electron microscopy (EM). Class I lupus nephritis is believed to be a rare manifestation, and its existence is challenged by many pathologists.

The mildest form of lupus nephritis, class II, is characterized by a mild or moderate increase of mesangial cells accompanied by mesangial deposits of immunoglobulins and complement. These mesangial deposits are regarded as the most characteristic immunopathologic feature of lupus nephritis. The more severe forms of lupus nephritis not only show an increase of mesangial deposits but also deposits

along the capillary loops. Dependent on the severity of the morphologic damage, the extent of immune deposits, and whether less or more than half of glomeruli are affected, this form of proliferative lupus nephritis was divided into focal segmental glomerulonephritis (class III) and diffuse glomerulonephritis (class IV). The distinction between class III and class IV, however, is arbitrary; it also is unreliable in clinical practice. Therefore, the recent modification of the WHO classification (1995) proposes a new definition of classes III and IV lupus nephritis.

All more severe forms of proliferative lupus nephritis are included in class IV and specified as mild, moderate, or severe, depending on the severity on the glomerular damage. In active lesions there occurs a large increase in mesangial cells; an influx of monocytes or granulocytes; so-called hyaline thrombi in the capillary lumina; and necrosis of the capillary loops, defined as severe mesangial proliferative or endocapillary proliferative glomerulonephritis, and sometimes with varying degrees of extracapillary proliferation. In chronic disease, mesangiocapillary lesions are present with extensive subendothelial deposits (*wire loops*), duplication of the glomerular basement membrane (GBM), cellular interposition, and varying increases of mesangial cells and matrix. On electron microscopy, the deposits have a homogeneous or fine granular structure with sometimes organized "fingerprint" patterns. Frequently, tubuloreticular structures are present in the cytoplasm of endothelial cells, inclusions also found in viral infections, such as human immunodeficiency virus, and related to  $\gamma$ -interferon. Class III is now restricted to patients with active or sclerosing focal segmental necrotizing lesions accompanied by mild increase of mesangial cells.

Membranous lupus nephritis (class V) is hardly distinguishable from the idiopathic form of lupus nephritis. However, membranous lupus nephritis often is accompanied by a mild or moderate increase of mesangial cells or matrix, and the subepithelial deposits contain more classes of immunoglobulins (so-called full-house) than does the idiopathic form. In addition, it is not unusual to find small subendothelial and mesangial deposits. The subepithelial deposits are either globally distributed along the glomerular basement membrane (GBM) or more segmentally localized. The subepithelial deposits also are a frequent occurrence in class IV lupus nephritis. According to the most recent version of the WHO classification [47], class V is now restricted to cases that are predominantly characterized by subepithelial immune complexes. More advanced or end-stage cases of focal and diffuse proliferative lupus nephritis characterized by a pronounced sclerosis and hyalinosis are classified as class VI lupus nephritis.

Interstitial fibrosis, accompanied by tubular atrophy and influx of mononuclear cells, is a frequent finding, especially in the chronic forms of classes III, IV, and V. Lesions resembling chronic tubulointerstitial nephritis without glomerular alterations also have been described in some patients with SLE. In these cases, on immunofluorescence, it is not unusual to find granular immune complexes in the tubular basement membranes. Reference 47 provides additional information on the 1995 revised WHO classification. Examples of the different forms of SLE nephritis are presented in Figs. 11-14 to 11-20. (From Churg and coworkers [47]; with permission.)

### NATIONAL INSTITUTES OF HEALTH HISTOLOGIC SCORING SYSTEM FOR ACTIVITY AND CHRONICITY IN LUPUS NEPHRITIS

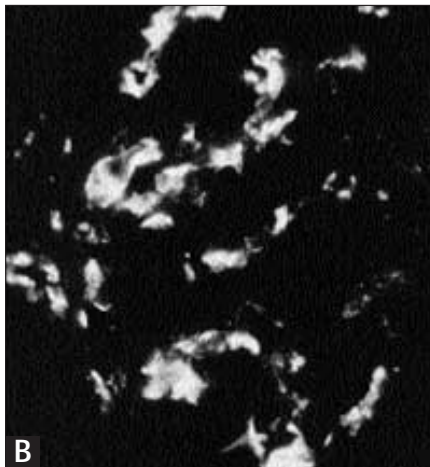
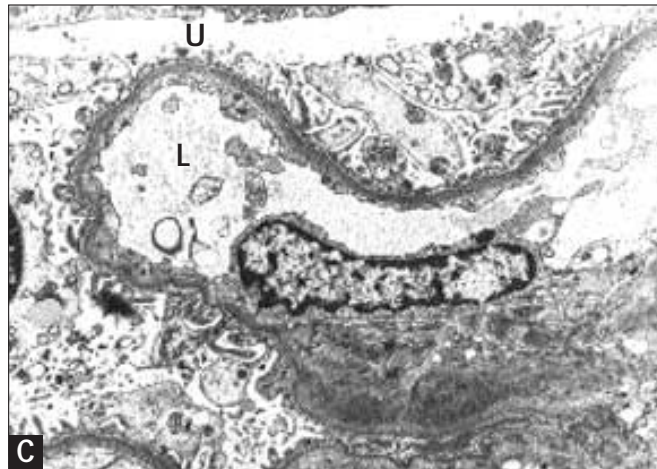
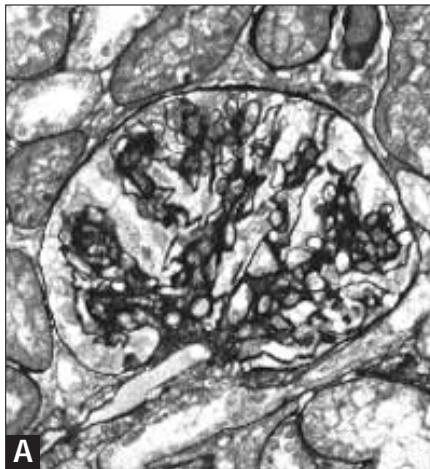
	Activity index	Chronicity index
Glomerular	Endocapillary hypercellularity Leukocyte infiltration Fibrinoid necrosis, karyorrhexis* Cellular crescents*	Glomerular sclerosis Fibrous crescents
Tubulointerstitial	Hyalin deposits, wire loops Mononuclear cell infiltration	Fibrosis Tubular atrophy
Maximal score	24	12

Scoring per item from 0 to 3; for parameters with asterisks, the score is doubled.

### FIGURE 11-13

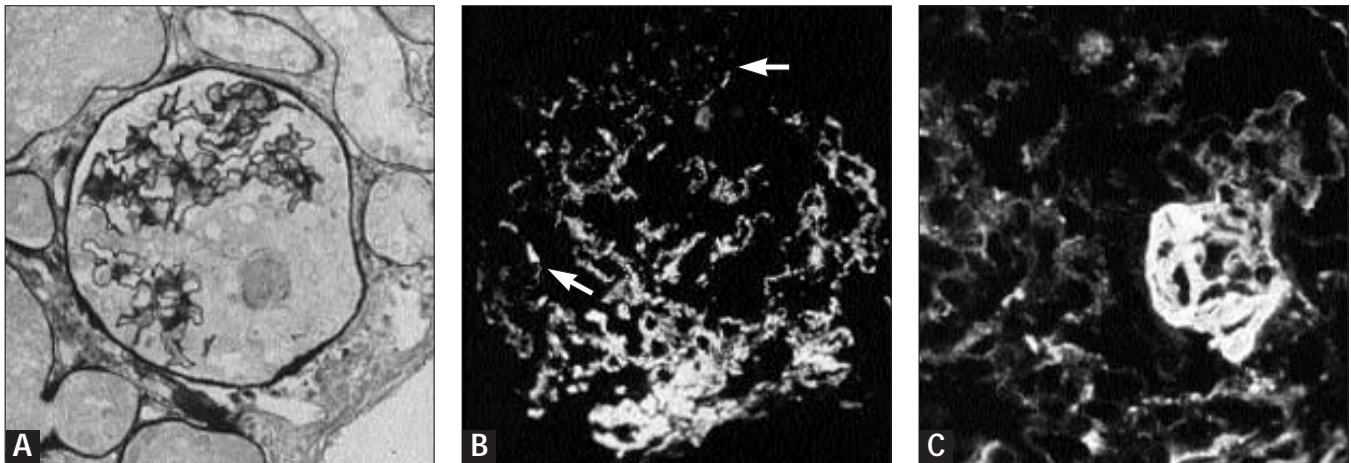
The value of the analysis of lupus glomerulonephritis according to the World Health Organization (WHO) classification for prognosis and treatment can be enhanced by including indices of activity and chronicity. These indices were proposed in the National Institutes of Health (NIH) index [49]. The extent of the active and chronic lesions is assessed according to the scoring system here. A chronicity index of 3 or higher and an activity index of 12 or higher are associated with a significantly greater risk for the development of end-stage renal disease [14].

## Histology of Lupus Nephritis



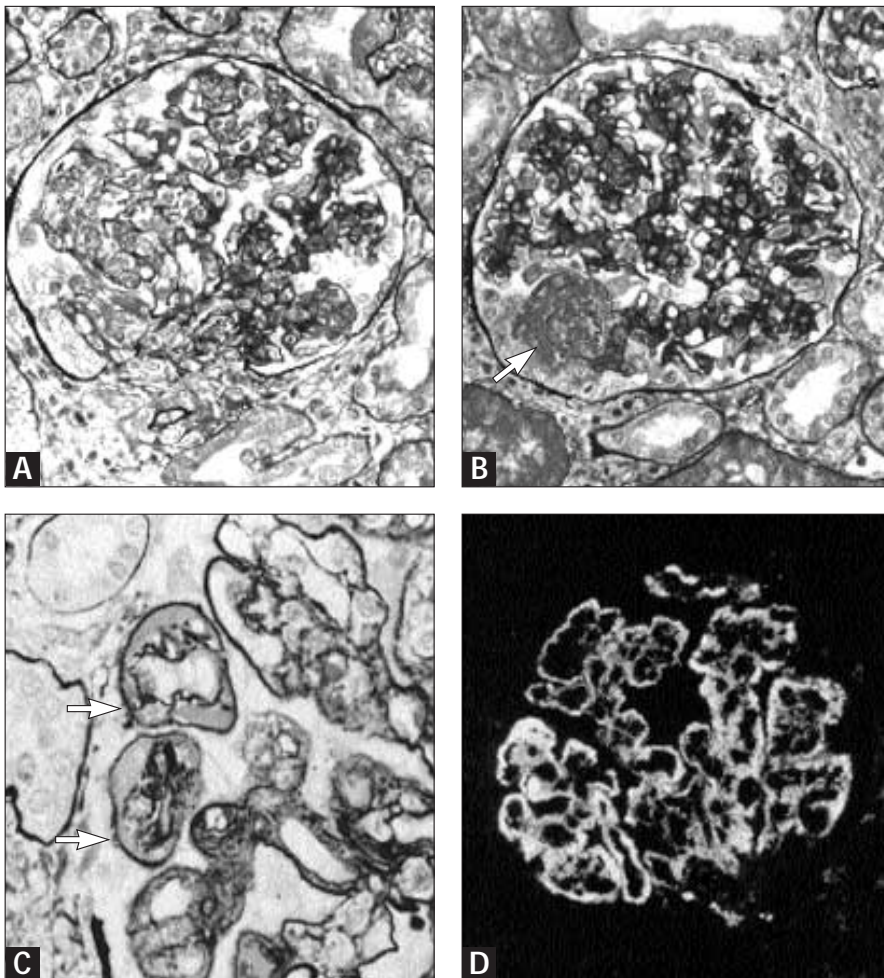
### FIGURE 11-14

Lupus nephritis class II. **A**, A moderate increase of mesangial cells is seen on light microscopy. **B**, Immunofluorescence. Mesangial deposits of immunoglobulin G. **C**, Electron microscopy shows electron-dense deposits restricted to the mesangial area. L—capillary lumen; U—urinary space. (Panel A, methenamine silver. Original magnification  $\times 400$ ,  $\times 520$ ,  $\times 10,000$ , respectively.)

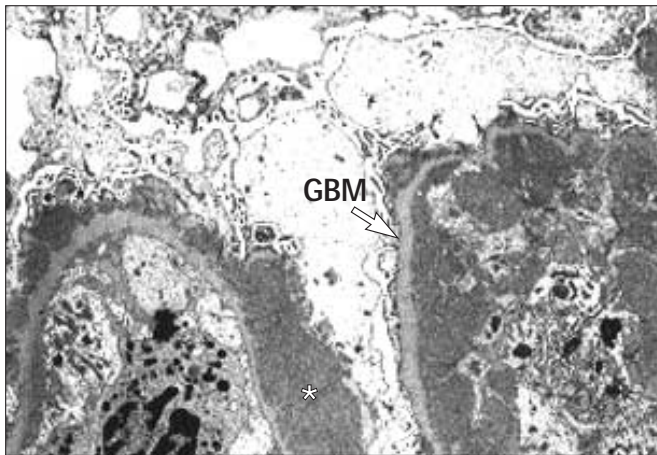
**FIGURE 11-15**

Lupus nephritis class III. **A**, Segmental necrotizing lesion surrounded by an increased number of epithelial cells. **B**, Immunofluorescence. Next to mesangial deposits of immunoglobulin G there also are deposits in the periphery of some loops (*arrows*). **C**, Immunofluorescence. Fibrin

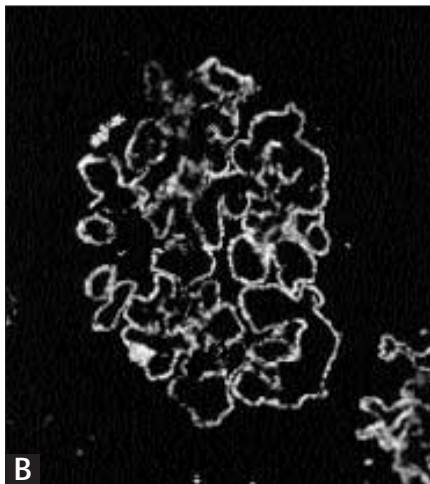
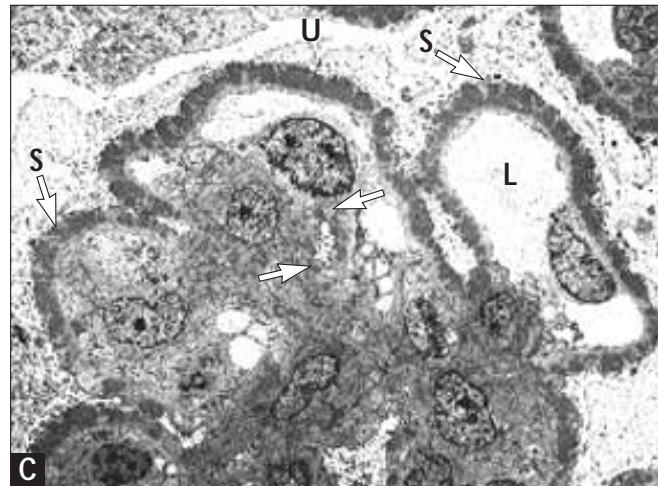
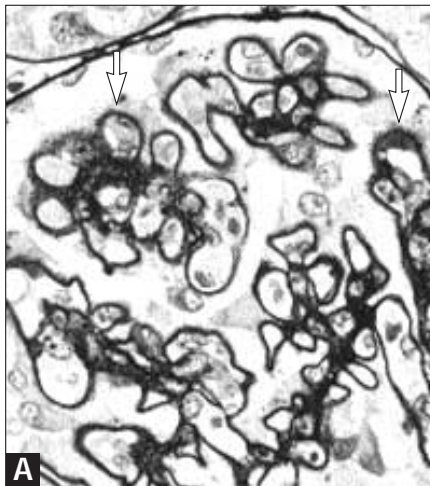
deposits in a necrotizing lesion. According to the 1995 modified World Health Organization classification, this is a characteristic immunopathologic lesion of class III lupus nephritis. (*Panel A*, methenamine silver. Original magnification  $\times 400$ ,  $\times 400$ ,  $\times 520$ , respectively.)

**FIGURE 11-16**

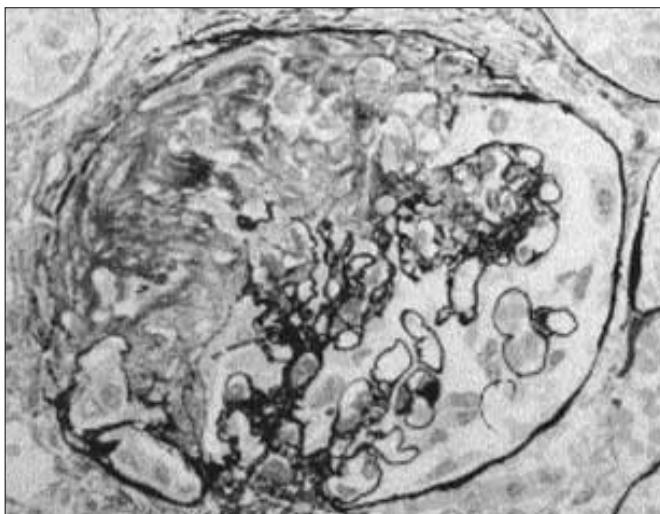
Lupus nephritis class IV on light microscopy and immunofluorescence. **A** and **B**, Diffuse endocapillary proliferative pattern of injury with an increase of mesangial cells and an influx of mononuclear cells and some granulocytes. *Panel B* shows a necrotizing lesion (*arrow*). **C**, A mesangio-capillary pattern of injury with duplication of the glomerular basement membrane (GBM), an increase of mesangial cells and matrix, and massive subendothelial deposits (*wire loops*). In addition, spikes (membranous component) can be found on the epithelial side of the GBM (*arrow*). **D**, Immunofluorescence. The characteristic pattern of the immune deposits (immunoglobulin G) of class IV lupus nephritis, predominantly localized along the capillary wall. (*Panels A, B, C*, methenamine silver. Original magnification  $\times 360$ ,  $\times 360$ ,  $\times 740$ ,  $\times 300$ , respectively.)

**FIGURE 11-17**

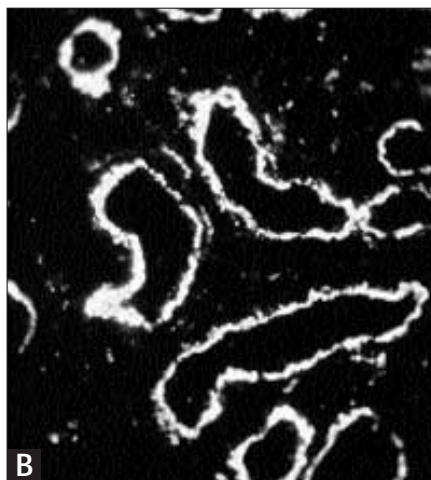
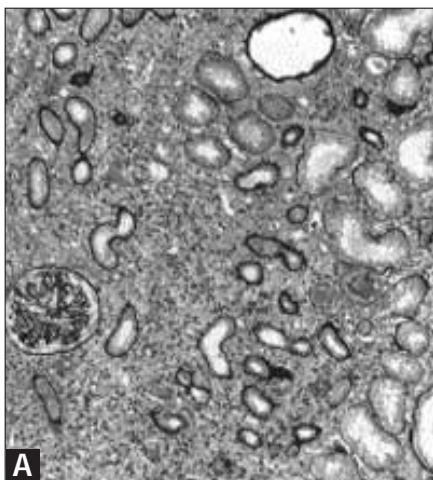
Lupus nephritis class IV. A representative electron micrograph shows diffuse lupus nephritis with subendothelial and mesangial electron-dense deposits with additional massive subepithelial deposits (*asterisk*). GBM—glomerular basement membrane; U—urinary space. (Original magnification  $\times 12,000$ .)

**FIGURE 11-18**

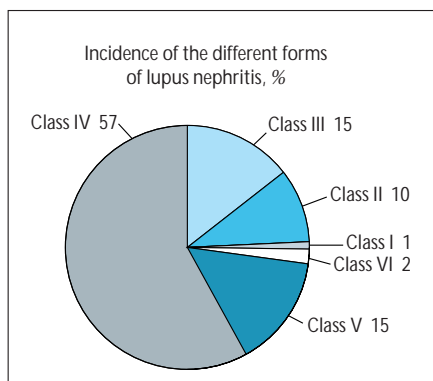
Lupus nephritis class V. **A**, Discrete spikes on the epithelial side of the glomerular basement membrane (GBM) (*arrows*), and a moderate increase of mesangial cells. **B**, Immunofluorescence. Fine granular deposits of immunoglobulin G along the capillary wall in a characteristic membranous pattern. **C**, Electron micrograph reveals electron-dense deposits on the epithelial side of the GBM between spikes. Between an increased number of mesangial cells small deposits also are present (*arrows*). L—capillary lumen; S—spikes; U—urinary space. (*Panel A*, methenamine silver, original magnification  $\times 700$ ,  $\times 400$ ,  $\times 3100$ , respectively.)

**FIGURE 11-19**

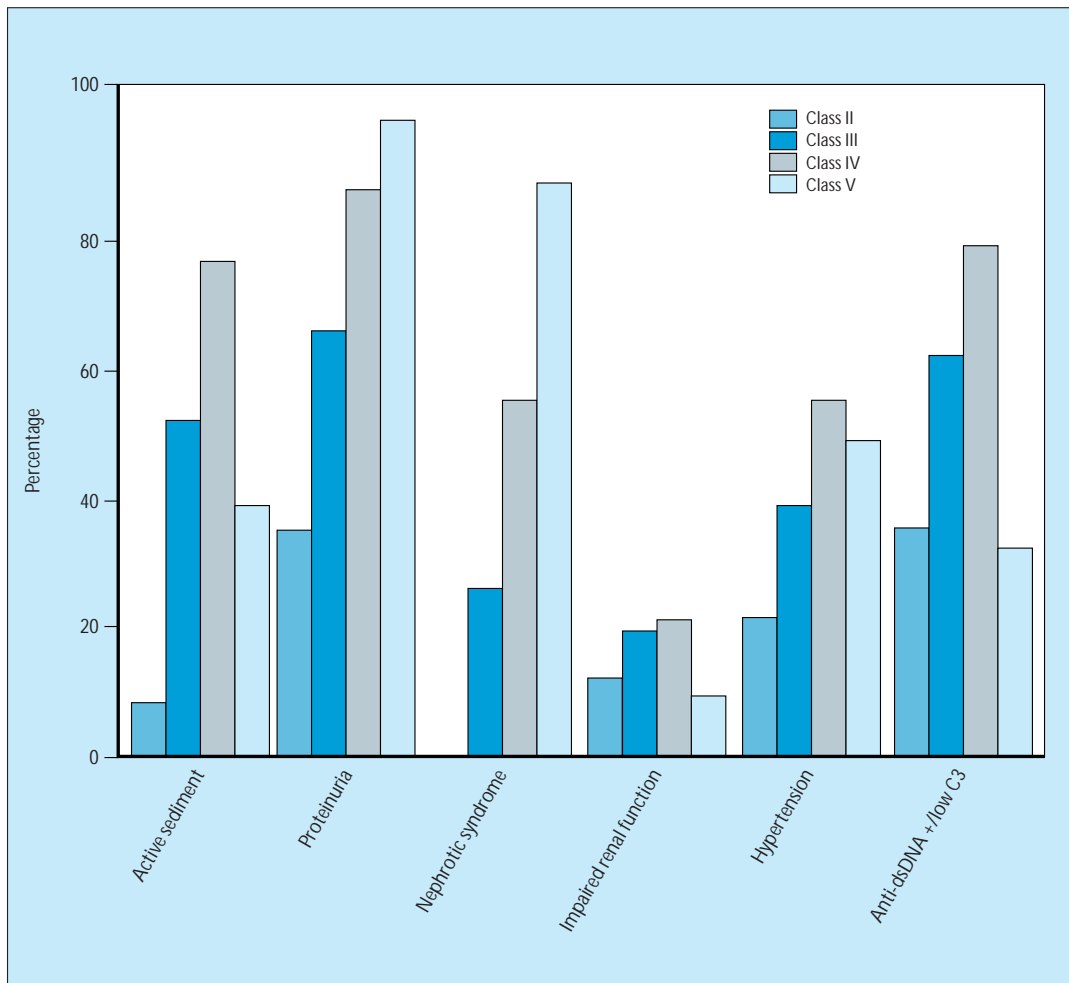
Lupus nephritis class VI. Sclerosing glomerulonephritis with extensive sclerosis of most of the capillary tuft. (Methenamine silver, original magnification  $\times 700$ .)

**FIGURE 11-20**

Chronic tubulointerstitial nephritis. **A**, Extensive interstitial fibrosis accompanied by tubular atrophy and a mononuclear cell infiltration **B**, Immunofluorescence. Granular deposits of immunoglobulin G in tubular basement membranes. (Panel **A**, methenamine silver, original magnification  $\times 100$ ,  $\times 400$ , respectively.)

**FIGURE 11-21**

Incidence of the different forms of lupus nephritis classified according to the World Health Organization (WHO) classification. The incidence of the different forms categorized according to the WHO classification depends on patient selection and ethnic background. The percentages represent an average of the data reported in the literature. Most patients have a diffuse proliferative form of lupus nephritis (WHO class IV).



**FIGURE 11-22**

Incidence of renal manifestations and serologic abnormalities in the different forms of lupus nephritis. The clinical manifestations of lupus nephritis are not different from other forms of glomerulonephritis and include a nephritic sediment (dysmorphic erythrocytes and erythrocyte casts), proteinuria or nephrotic syndrome, impaired renal function, and hypertension. Although certain clinical manifestations are more prevalent in certain forms (nephrotic syndrome for World Health Organization (WHO)

class V, nephritic sediment for WHO class IV), it is clear that on the basis of clinical symptoms it is not possible to classify the form of nephritis correctly. This inability underlines the necessity for obtaining a renal biopsy specimen. In addition, listed are the occurrence of both a positive result on performing a Farr assay and a low complement 3 level for the different forms of lupus nephritis. Anti-dsDNA—anti-double-stranded DNA. (*Adapted from Appel et al. [50]*).

### TREATMENT OF THE DIFFERENT FORMS OF LUPUS NEPHRITIS

World Health Organization classification	Treatment options
I	Treatment guided by extrarenal lesions
II	Corticosteroids:
III, IV	Cyclophosphamide pulses, oral prednisone Methylprednisolone pulses, azathioprine, low doses oral prednisone
V	Corticosteroids (and azathioprine or cyclophosphamide)
VI	No further immunosuppression ? Supportive treatment

**FIGURE 11-23**

Treatment options for the different forms of lupus nephritis are summarized. Only for World Health Organization (WHO) classes III, IV, and V are a limited number of prospective studies available. For the other forms, a balanced compilation is made from the literature and personal experience. Reference 14 supplies a more detailed analysis of the therapeutic options. For class I lupus nephritis, no specific renal therapy is necessary; treatment is dictated by the presence of extrarenal symptoms.

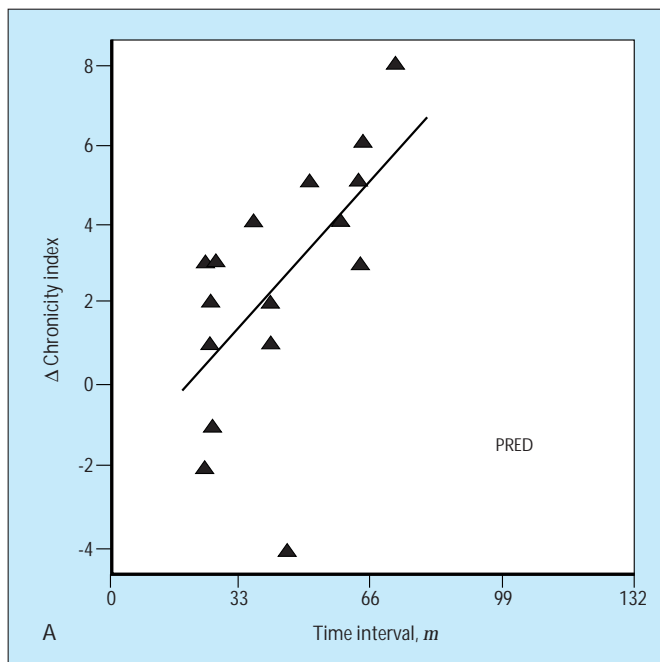
In general, patients with class II lupus nephritis respond satisfactorily to monotherapy with oral corticosteroids. The patient, however,

must be monitored for transition to a more severe form, which is generally heralded by worsening of clinical renal symptoms.

For patients with classes III and IV lupus nephritis, corticosteroid monotherapy is not sufficient (Fig. 11-24). Cytotoxic immunosuppressive therapy, either cyclophosphamide or azathioprine, should be added to the treatment. The choice of one of these drugs over the other is discussed in Figures 11-24, 11-25, and 11-26.

According to a recent analysis [51], patients with a pure membranous lupus nephritis without a proliferative component (class V, according to the 1995 revised WHO classification) respond satisfactorily to corticosteroid monotherapy. Patients who have a membranous nephropathy with a proliferative component (formerly classified as WHO class VC or VD) have a much worse prognosis and should be treated as are patients with a class IV lupus nephritis. When a patient with class V (A or B) lupus nephritis does not respond to corticosteroids, addition of azathioprine or cyclophosphamide should be considered (as in idiopathic membranous glomerulonephritis, in which oral treatment seems to be superior over monthly intravenous pulses [52–54]). When cyclophosphamide treatment is initiated the therapeutic response should be evaluated after 6 months, and the drug should be discontinued if no improvement has occurred [55].

Treatment of WHO class VI nephritis should be balanced on weighing the risks of intensification of immunosuppressive treatment and the expected benefits. When renal function already is strongly impaired and the renal biopsy specimen shows predominantly chronic irreversible lesions, further deterioration of renal function may be unavoidable. Therefore, an increase in immunosuppressive therapy is questionable. This approach is strengthened by the fact that lupus disease activity mostly subsides during renal replacement therapy. Results of renal transplantation are good, and the disease rarely recurs after transplantation [14].



**FIGURE 11-24**

Change in chronicity index in repeat biopsies after treatment with prednisone (PRED) alone or prednisone and cytotoxic drugs (CTD). The addition of cytotoxic drugs to the treatment regimen of patients with World Health Organization (WHO) class III or IV nephritis clearly improves renal and patient survival [56,57]. The pathophysiologic basis for this beneficial effect is illustrated, displaying the change in chronicity index between the first and second kidney biopsies over time. As can be seen during prednisone monotherapy, there is a clear increase of the chronicity index (A);

(Continued on next page)

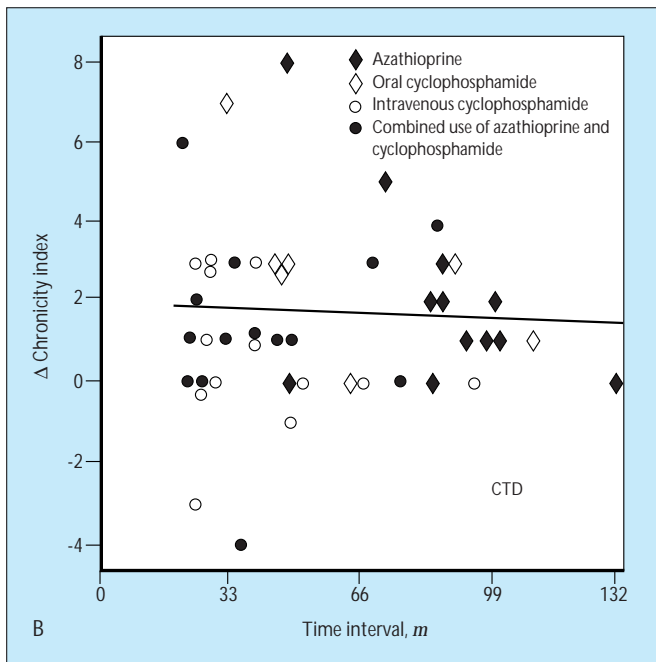


FIGURE 11-24 (Continued)

whereas in patients treated with prednisone and cytotoxic drugs (B) the chronic lesions, on average, do not progress. Various studies have shown that this chronicity index is the strongest predictor of development of end-stage renal disease [14]. (From Balow *et al.* [58]; with permission.)

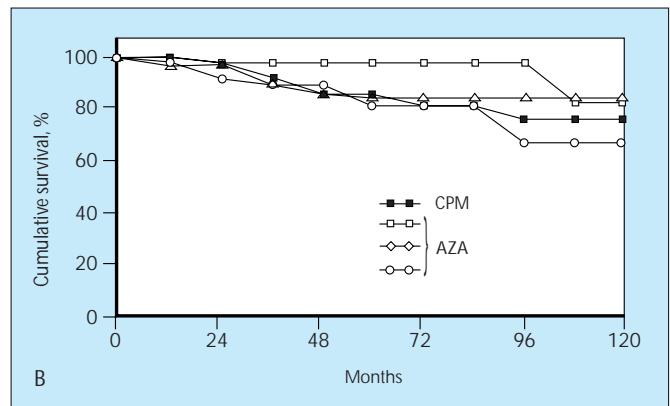
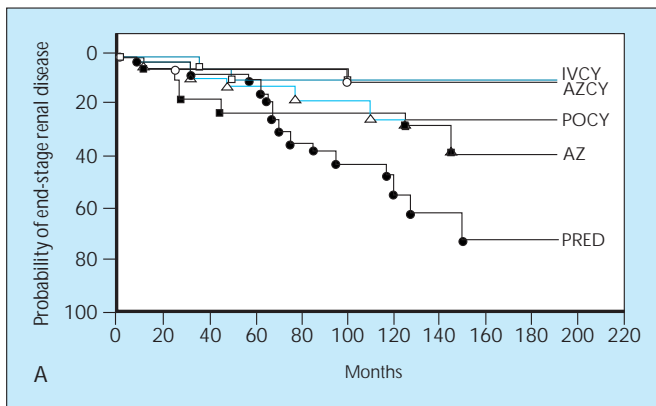


FIGURE 11-25

**A**, The probability of end-stage renal disease in patients with proliferative lupus nephritis treated with different drug regimens. This update of the prospective trial by the National Institutes of Health (NIH) on the treatment of these patients clearly demonstrates that prednisone monotherapy, in a significantly greater proportion of patients, leads to the development of end-stage renal disease compared with patients on regimens containing cytotoxic drugs. The results between azathioprine and drug regimens containing cyclophosphamide are not significantly different. Note that in up to 7 years the results do not differ between the different treatment groups. From these studies it is clear that although the therapeutic efficacy is equal for the three treatment regimens containing cyclophosphamide, less side effects occurred in patients treated with intravenous pulses of cyclophosphamide.

**B**, Renal survival in patients with World Health Organization (WHO) class IV lupus nephritis treated with either cyclophosphamide (CPM) or azathioprine (AZ). The NIH trial [56,59] did not reveal a significant difference between the therapeutic efficacy of cyclophosphamide and azathioprine (A). However, the side

effects of both drugs are not identical. Cyclophosphamide has a greater bone marrow toxicity, leads to amenorrhea in many patients, is teratogenic, and displays a unique urothelial toxicity (hemorrhagic cystitis and bladder carcinoma). Therefore, prospective studies comparing cyclophosphamide with azathioprine are warranted but not available. The results of the NIH trial are compared with those reported for azathioprine [57,60–62]. This analysis, carried out by Cameron [57], does not reveal a significant difference between cyclophosphamide and azathioprine. A recent meta-analysis [63] again showed that monotherapy with prednisone was inferior to treatment with cytotoxic drugs in combination with steroids. However, as in the NIH trial and the analysis by Cameron, no differences were found between cyclophosphamide and azathioprine in preserving renal function. AZ—azathioprine; AZCY—combined therapy with azathioprine and cyclophosphamide; IVCY—intravenous pulses of cyclophosphamide; POCY—oral cyclophosphamide. (Panel A from Steinberg and Steinberg [59]; with permission. Panel B from Cameron [57]; with permission.)

## RISK FACTORS FOR DEVELOPMENT OF END-STAGE RENAL DISEASE IN SYSTEMIC LUPUS ERYTHEMATOSUS

Clinical characteristics	Treatment characteristics	Histologic characteristics	Demographic characteristics
Elevated initial serum creatinine	No normalization of elevated creatinine	World Health Organization class IV	Male gender
Nephrotic range proteinuria	Treatment with prednisone only	Activity index $\geq 12$	Black race
Low C3		Chronicity index $\geq 3$	Age $\leq 24$ y
Hematocrit $\leq 26\%$			Low socioeconomic status
Hypertension			
Persistent disease activity			

FIGURE 11-26

These risk factors were identified in different analyzes in different patient groups. Not all these parameters were confirmed in all studies, probably because of differences in definitions used, composition of the cohort studied, duration of

follow-up, and so on. The most powerful predictors seem to be an elevated serum creatinine level at entry into the trial, a chronicity index of 3 or higher, and persistent or remitting renal disease activity [14,64].

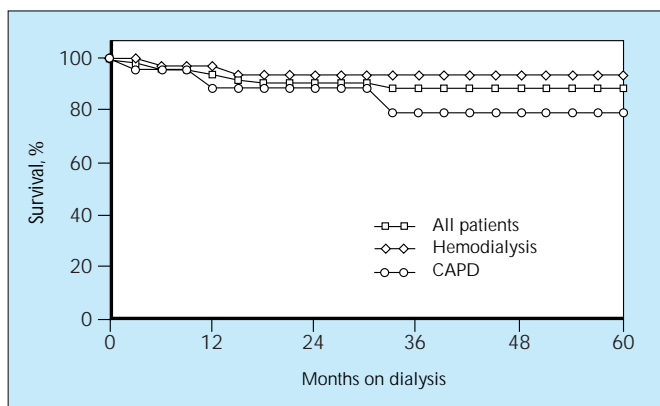


FIGURE 11-27

Survival of patients with systemic lupus erythematosus (SLE) on dialysis. Although initially dialysis treatment was not offered to patients with SLE because of the systemic nature of their illness, it later became clear that patients with SLE tolerate dialysis treatment as well as do patients with non-SLE renal diseases. The overall patient survival is good (90% at 5 years), and no differences exist in patient survival between those treated with continuous ambulatory peritoneal dialysis (CAPD) as compared with hemodialysis. (Data from Nossent *et al.* [65].)

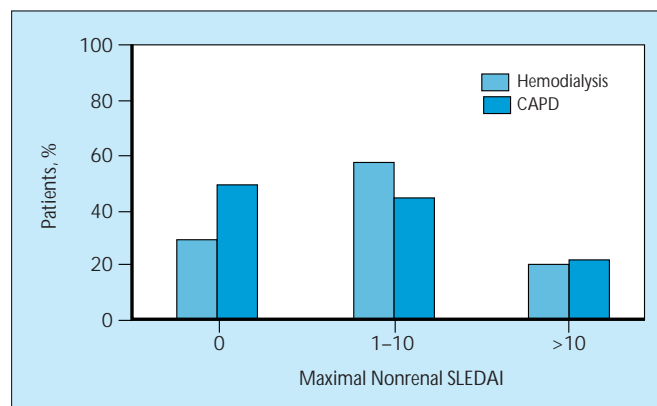
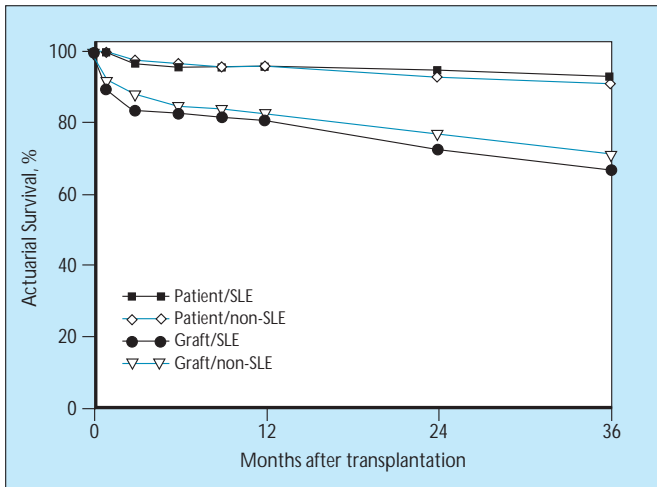


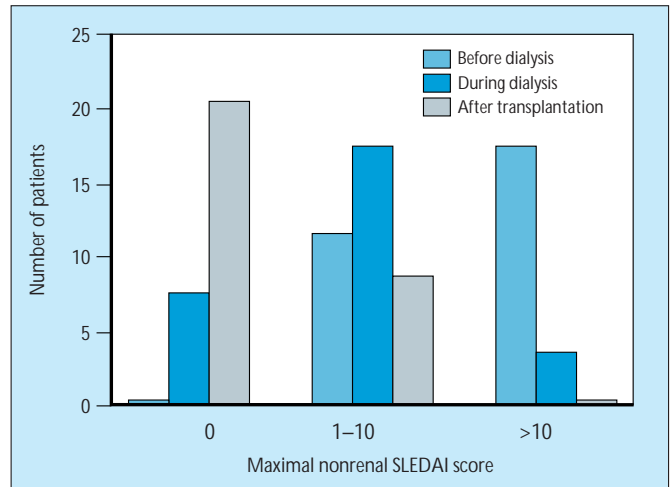
FIGURE 11-28

Severity of systemic lupus erythematosus (SLE) disease activity during hemodialysis or continuous ambulatory peritoneal dialysis (CAPD). Lupus disease activity generally decreases during dialysis treatment. As assessed by the SLE Disease Activity Index (SLEDAI) [66], the maximal nonrenal SLEDAI decreased during dialysis in 49% of patients, remained stable in 42%, and showed progression in 9%. Despite the fact that immunosuppression was minimized, in 90% of patients cytotoxic drug therapy was discontinued and in 55% the dose of steroids was considerably reduced [65]. In addition, in this analysis no differences were found in disease activity in patients treated with either hemodialysis or CAPD. The maximal nonrenal SLEDAI scores were divided in three groups: 0, no extrarenal disease activity; 1 to 10, moderate extrarenal disease activity; over 10, high extrarenal disease activity.



**FIGURE 11-29**

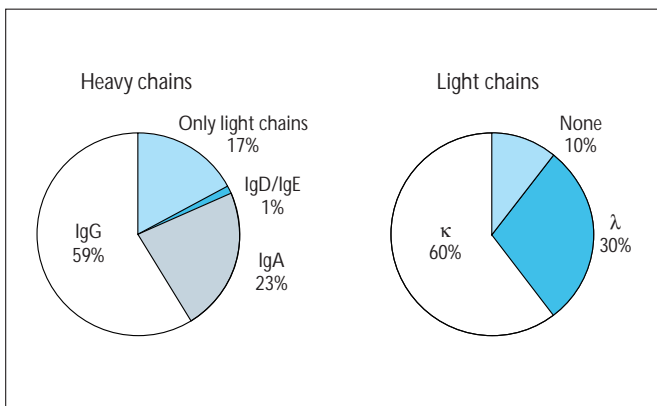
Graft and patient survival after renal transplantation in patients with systemic lupus erythematosus (SLE). For this analysis only patients with first transplantations using a cadaveric donor kidney were included. Both graft and patient survival were calculated for 165 patients with SLE who received transplantation between 1984 and 1992. These data are compared with the results in 21,726 patients with non-SLE glomerular diseases who received transplantation in the same time period. Both graft and patient survival were not significantly different between the two groups. (From Berden [14]; with permission. Data from G. Persijn, Eurotransplant, Leiden, the Netherlands.)



**FIGURE 11-30**

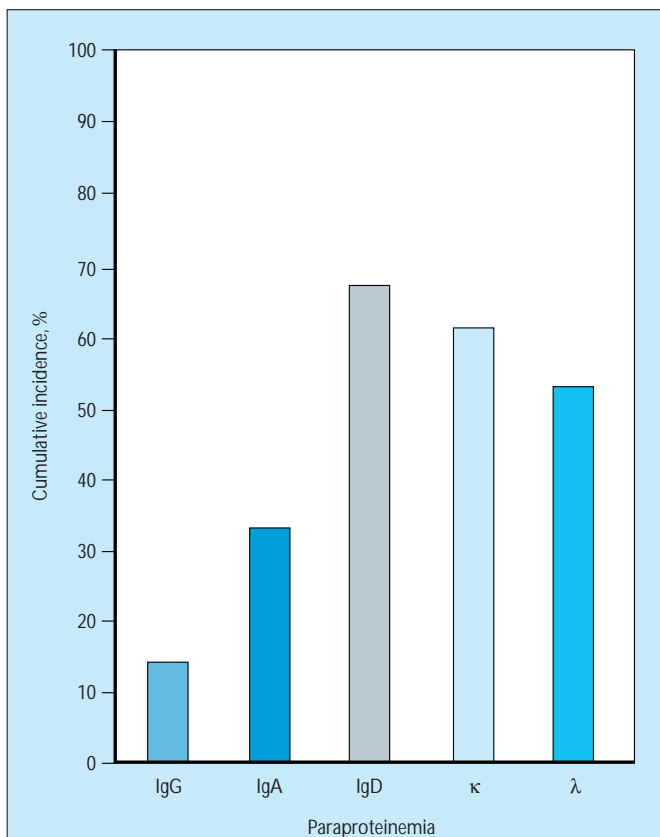
Lupus disease activity after renal transplantation. Disease activity was assessed in 28 patients with systemic lupus erythematosus (SLE) by calculating the maximal nonrenal SLE Disease Activity Index (SLEDAI) in the time periods before dialysis, during dialysis, and after renal transplantation. The maximal nonrenal SLEDAI scores were divided in three groups: 0, no extrarenal disease activity; 1 to 10, moderate extrarenal disease activity; over 10, high extrarenal disease activity. Note that before dialysis all patients had extrarenal lupus disease activity but that after renal transplantation no patient had high disease activity. These data illustrate that the decrease in disease activity that begins during dialysis treatment continues after renal transplantation. In addition, recurrence of lupus nephritis after renal transplantation is rare [67]. (From Berden [14]; with permission. Data from Nossent *et al.* [68].)

## Renal Involvement in Dysproteinemias

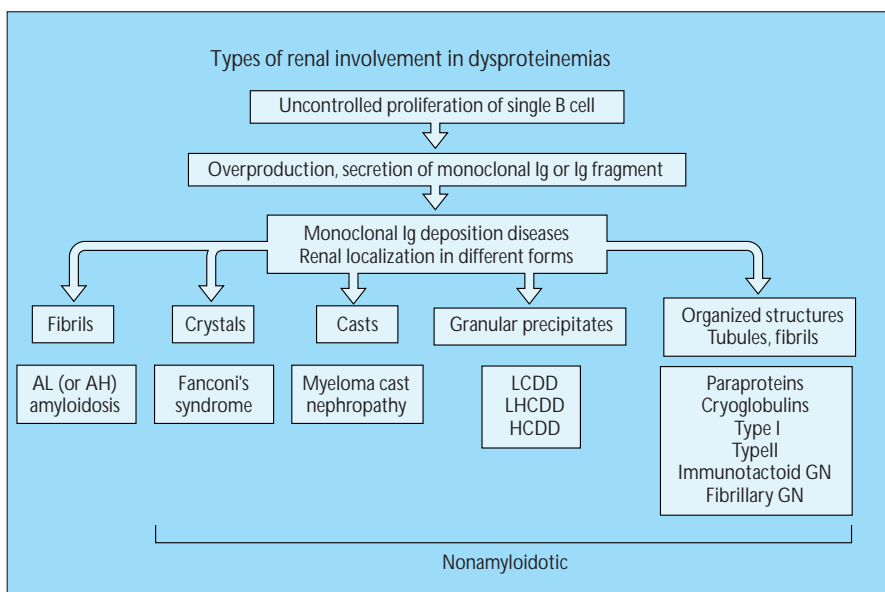


**FIGURE 11-31**

Frequency of isotypes of heavy and light chains produced by non-immunoglobulin (Ig) M myelomas. Most paraproteins produced belong to the IgG class. Note that in approximately 20% of myelomas only light chains are produced, of which two thirds belong to the κ isotype and one third to the λ isotype [69,70]. These frequency distributions mirror those of Ig classes and light chain isotypes in the serum.



**FIGURE 11-32** Incidence of renal involvement in dysproteinemias. This incidence is not identical for all paraproteinemias. The reason is directly related to the frequency and degree of light chain proteinuria [71]. Ig—immunoglobulin. (From Pruzanski [72]; with permission.)



**FIGURE 11-33** Types of renal involvement in dysproteinemias. The uncontrolled proliferation of a B-cell clone leads to overproduction of a monoclonal immunoglobulin (Ig), either an intact molecule or fragments thereof (light or heavy chains). These molecules can

deposit in the kidney and other vital organs, depending on the immunoglobulin class, light or heavy chain isotype, and other only partly understood physicochemical properties. The terminology used in these disorders is sometimes confusing and inconsistent. We use the definitions proposed by Gallo and Kumar [73]. All diseases characterized by deposits of monoclonal immunoglobulin-related material are named *monoclonal immunoglobulin deposition diseases* (MIDD). These deposits can occur in several forms, as outlined in the figure, and are identified by specific stains (such as congo red) and on immunofluorescence and electron microscopy. The histologic and clinical manifestations are dependent on the type of deposition. Included in this overview are fibrillary and immunotactoid glomerulonephritis, which in certain cases also show deposits containing monoclonal immunoglobulins. AH—heavy chain amyloidosis; AL—light chain amyloidosis; GN—glomerulonephritis; HCDD—heavy chain deposition disease; LCDD—light chain DD; LHCDD—light and heavy chain DD.

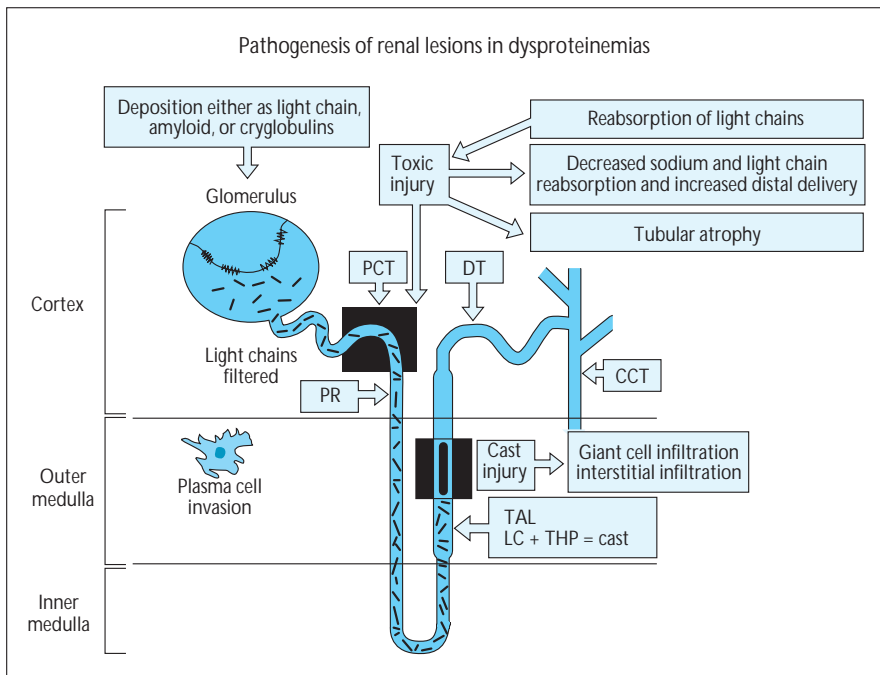


FIGURE 11-34

Pathogenesis of the different types of renal lesions in dysproteinemias. Paraproteins can deposit in the glomerular basement membrane (GBM) (and tubular basement membrane [TBM]) either as light or heavy chains, unmodified immunoglobulins, amyloids, or cryoglobulins. Because of their size of 22 kD, light chains are freely filtered through the GBM. These light chains are then reabsorbed by proximal tubular cells. This process can induce a cascade of

events. Because some of these light chains are relatively resistant to proteolysis, they can induce lysosomal damage. This damage can give rise to functional impairment of the proximal tubular cell, leading to a decreased resorptive capacity (eg, for sodium and light chains) and thereby increasing the distal delivery. When this lysosomal overload leads to intracellular crystal formation, Fanconi's syndrome may ensue. Increased distal delivery of light chains can then induce precipitation of light chains together with Tamm-Horsfall protein (THP) that is secreted in the loop of Henle. This precipitation is enhanced by an increased tubular fluid sodium chloride concentration. Other factors that enhance cast formation are listed in Figure 11-43. This intratubular cast formation leads to obstruction, tubular damage, and an interstitial inflammatory response with leakage of THP in the interstitium, inducing macrophage influx and giant cell formation. This entity is known as *myeloma cast nephropathy*. Finally, interstitial plasma cell invasion may occur in patients with myeloma, although this rarely leads to clinical symptoms and most often is only diagnosed by kidney biopsy specimen or is seen at autopsy. CCT—cortical collecting tubule; DT—distal tubule; LC—light chains; PCT—proximal convoluted tubule; PR—pars recta; TAL—thin ascending limb. (*Adapted from Winearls [69].*)

## Histology of Renal Lesions in Dysproteinemias

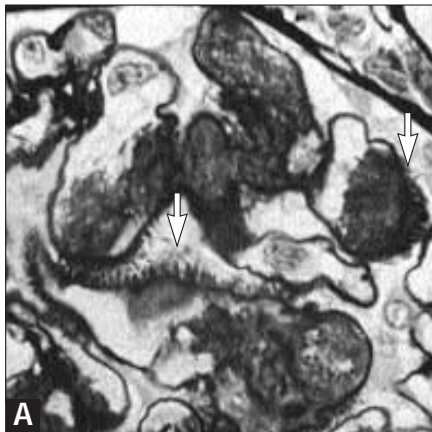
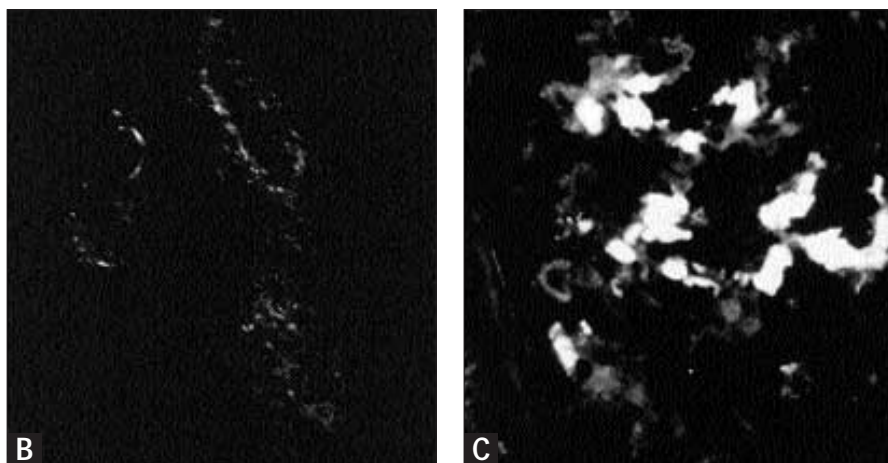


FIGURE 11-35 (see Color Plate)

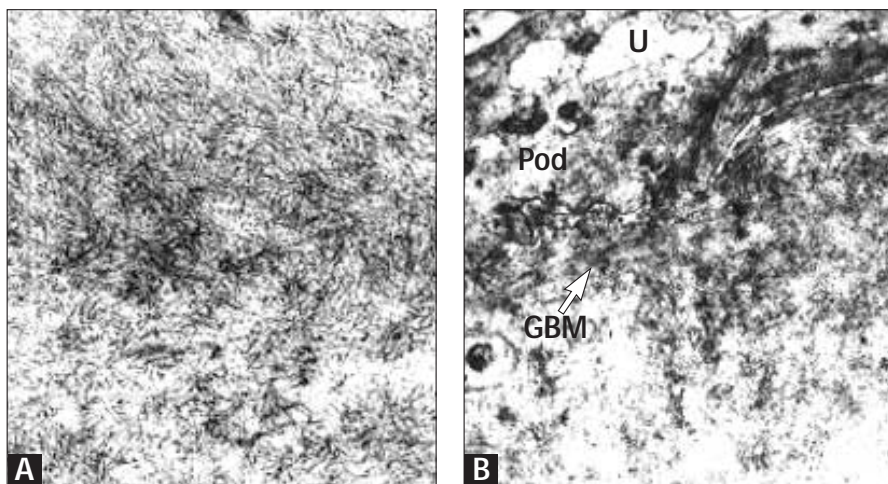
Light chain amyloidosis. Amyloid deposits associated with dysproteinemias are predominantly composed of fragments of the light chain variable region (AL amyloidosis) and very rarely of fragments of heavy chain variable regions (AH amyloidosis) [74]. On light microscopy, this type of amyloid is indistinguishable from amyloid of other origin. The homogeneous and amorphous material, faintly pink-stained with eosin or sometimes brownish-stained with methenamine silver, is deposited in the mesangium and along the capillary loops of the glomeruli, in the vessels, and occasionally in the interstitium. Amyloid frequently is localized in the glomerular basement membrane (GBM) as sheaths of fibrils or spicules that are larger and more irregularly arranged than are the spikes in membranous glomerulopathy. Congo red-stained sections viewed under polarized light reveal the specific apple-green birefringence, the gold standard for the diagnosis. Amyloid deposits are sometimes stained with commercially available antisera against light chains. In addition, these deposits also are positive for amyloid P, heparan sulfate proteoglycan, and apolipoprotein E. On electron microscopy, amyloid is composed of long, randomly distributed, nonbranching fibrils with diameters of 8 to 12 nm.

A, Amyloid deposits in mesangium and the capillary wall (arrows: spicules).

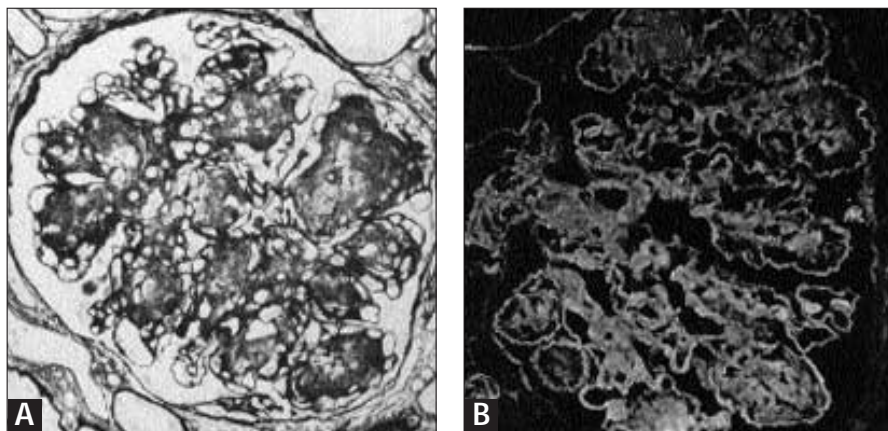
(Continued on next page)

**FIGURE 11-35 (Continued)**

**B**, Amyloid deposits in the renal arteries in a Congo red-stained slide and viewed under polarized light. Amyloid has an apple-green color. **C**, Immunofluorescence. Amyloid deposits in the mesangium stained with anti- $\lambda$  antibodies. (Panel A, methenamine silver. Original magnification  $\times 550$ ,  $\times 350$ ,  $\times 400$ , respectively.)

**FIGURE 11-36**

Light chain amyloidosis on electron microscopy. **A**, Characteristic fibrillar pattern of amyloid deposits. Long, randomly distributed, nonbranching fibrils with diameters of 8 to 12 nm. **B**, Amyloid fibrils in the capillary lumen and capillary wall with extension through the glomerular basement membrane (GBM) into the subepithelial space (arrow) fibrils arranged in parallel forming spicules. (Original magnification  $\times 48,000$ ,  $\times 20,000$ , respectively.)

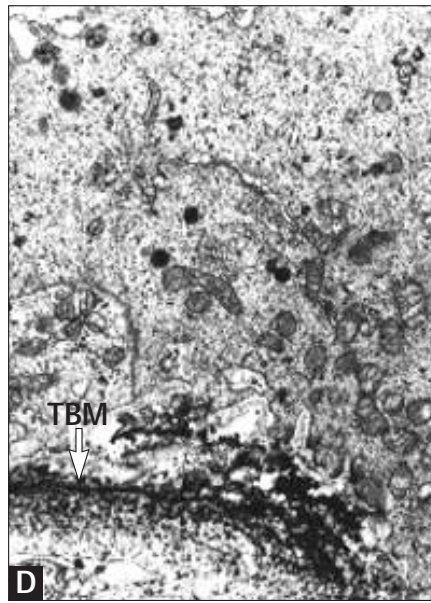
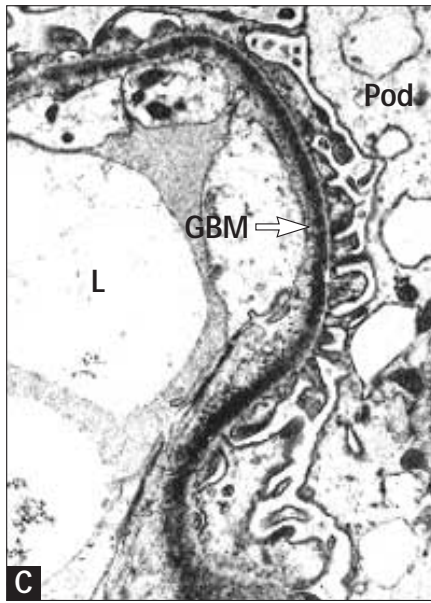
**FIGURE 11-37 (see Color Plate)**

Light chain deposition disease. In about 60% of patients with this renal lesion, nodular expansion of the mesangium is seen that resembles nodular diabetic nephropathy [75,76]. The nodules stained purple with periodic acid-Schiff (PAS) stain have a homogeneous appearance, and those stained with methenamine silver are pink-brownish in color. In a few cases, a more mesangiocapillary pattern of injury is present. The tubular basement membranes (TBMs) are

thickened, as seen in the PAS-stained sections. In the remaining cases, no renal lesions can be seen on light microscopy. On immunofluorescence, linear staining of basement membranes of glomeruli, tubuli, and vessels can be observed for one of the light chains ( $\kappa > \lambda$ ). In most cases, the TBMs are more heavily stained than are the glomerular basement membranes (GBMs). Congo red staining is negative for amyloid. On electron microscopy, fine granular electron-dense material can be found in most cases along the endothelial side of the GBM, in the mesangium, and along the interstitial side of the TBM. A few cases of heavy chain and of light and heavy chain deposition disease have been described, in most cases with identical morphologic characteristics as described in light chain deposition disease [77,78].

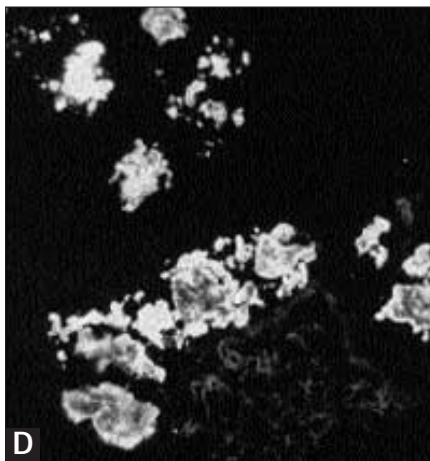
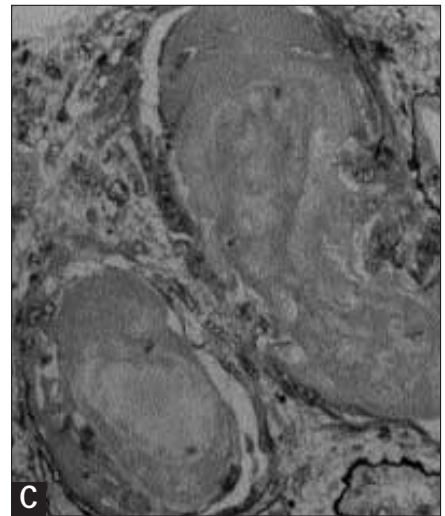
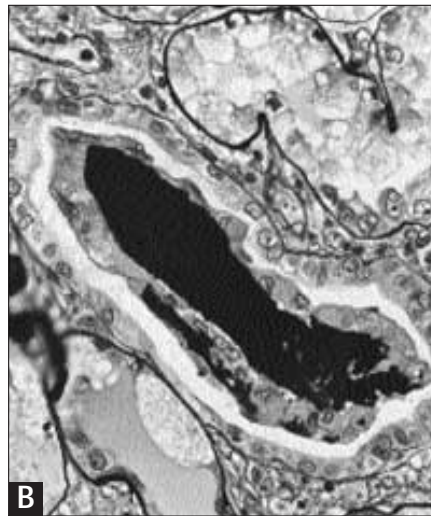
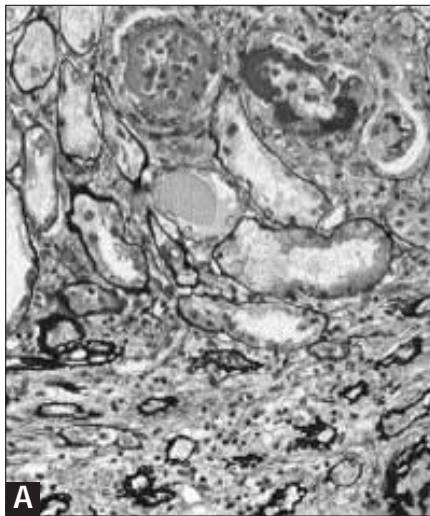
**A**, Nodular glomerulosclerosis with nodular increase of mesangial matrix. **B**, Linear staining of the GBM, mesangium, Bowman's capsule, and TBM for the  $\kappa$  light chain.

(Continued on next page)



**FIGURE 11-37 (Continued)**

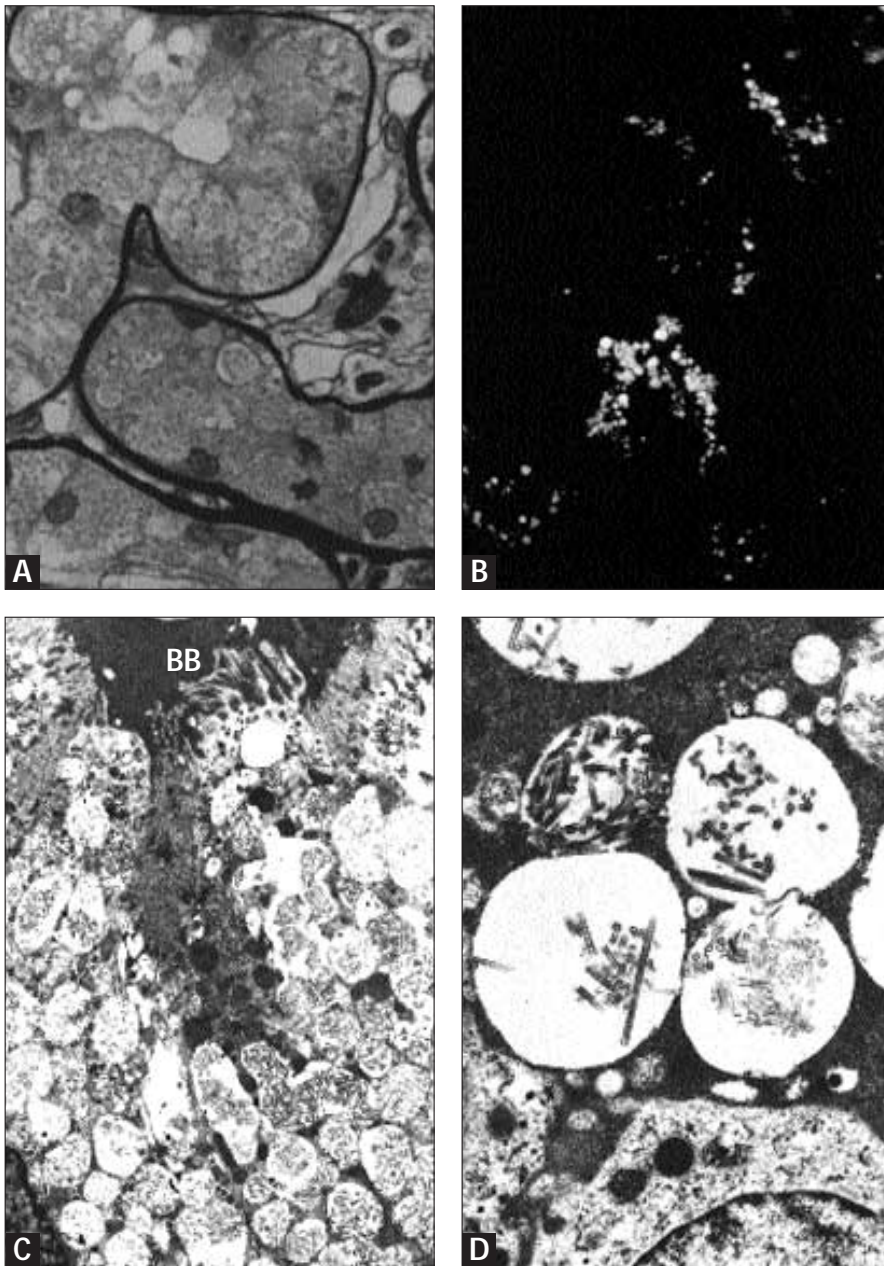
**C and D,** Electron-dense granular deposits in the GBM (C) and around the TBM (D). L—capillary lumen; Pod—podocyte. (Panel A, methenamine silver. Original magnification  $\times 400$ ,  $\times 400$ ,  $\times 15,000$ ,  $\times 6500$ , respectively.)



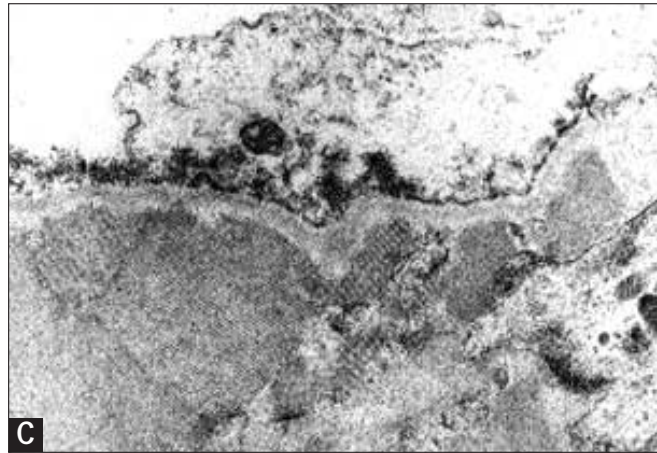
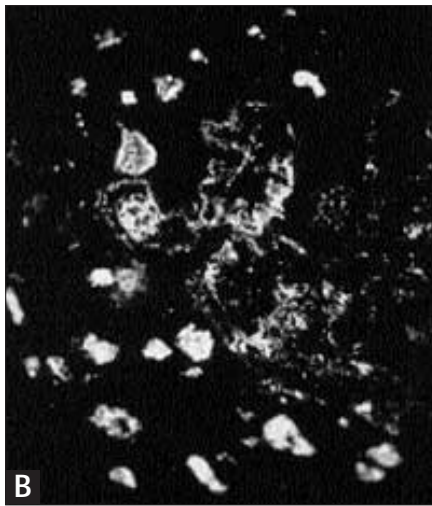
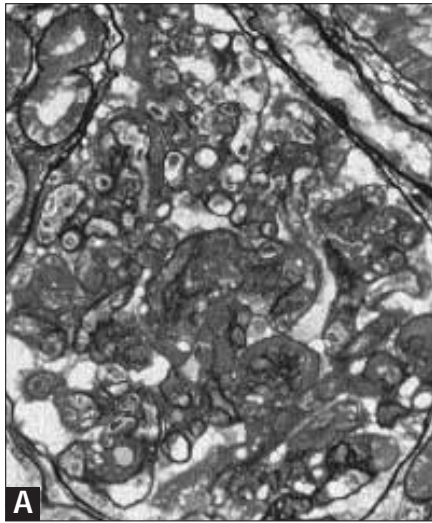
**FIGURE 11-38**

Cast nephropathy. The casts have a homogeneous, fractured, or crystalline appearance with sharp angular or irregular edges and are present in the distal and collecting tubules [73]. These casts are composed of aggregated  $\kappa$  or  $\lambda$  light chains mixed with Tamm-Horsfall protein (THP). Sometimes the tubular cells show necrosis accompanied by disruptions of the tubular basement membrane (TBM). Proximal tubular cells show hyaline droplets or vacuoles with needlelike, tubular, or complex crystalline material. Casts are surrounded by macrophages and multinucleated giant cells. On electron microscopy, the casts have a granular, homogeneous, or fibrillary appearance with occasional needlelike crystals. The fibrils that surround the casts are probably THP. In most cases, a varying degree of interstitial fibrosis exists, accompanied by mononuclear cell infiltration and tubular atrophy. Congo red staining for amyloid is usually negative. The glomeruli are normal.

**A,** Low magnification with casts in the distal tubules, and interstitial fibrosis with atrophic tubules (chronic tubulointerstitial nephritis). **B,** Brown-colored cast surrounded by macrophages. **C,** Eosinophilic homogeneous cast. **D,** Immunofluorescence. Casts are stained for  $\kappa$  light chains. (Panels A, B, C, methenamine silver. Original magnification  $\times 160$ ,  $\times 400$ ,  $\times 600$ ,  $\times 200$ , respectively.)

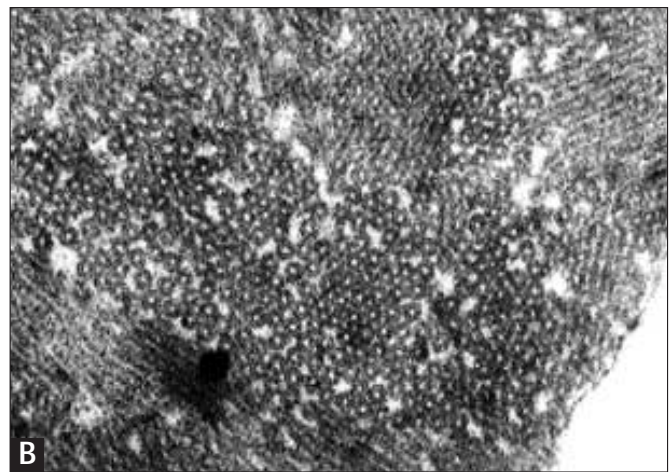
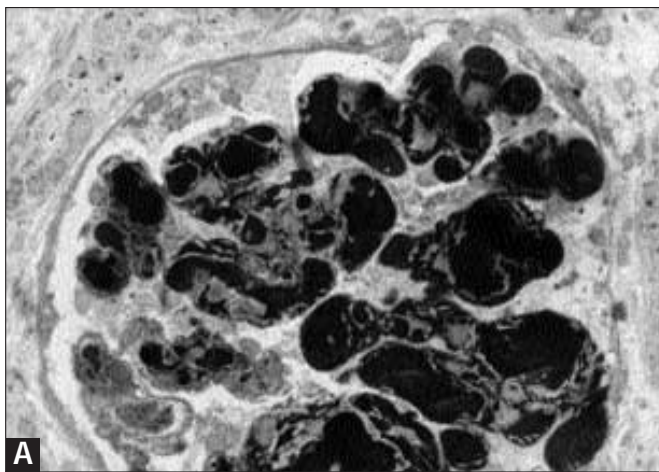
**FIGURE 11-39**

Fanconi's syndrome in a patient with  $\lambda$  light chain proteinuria. **A**, Vacuolization of proximal tubular epithelial cells. Vacuoles contain light-brown-colored material. **B**, Immunofluorescence. The granular material in tubular cells is stained for  $\lambda$  light chains. **C**, Low-power view of a proximal tubular epithelial cell with vacuoles containing organized or crystalline material. **D**, High-power view of the vacuoles containing tubular or ladderlike crystalline structures. BB—brush border. (Panel A, methenamine silver. Original magnification  $\times 600$ ,  $\times 400$ ,  $\times 7000$ ,  $\times 19,000$ , respectively.)



**FIGURE 11-40**

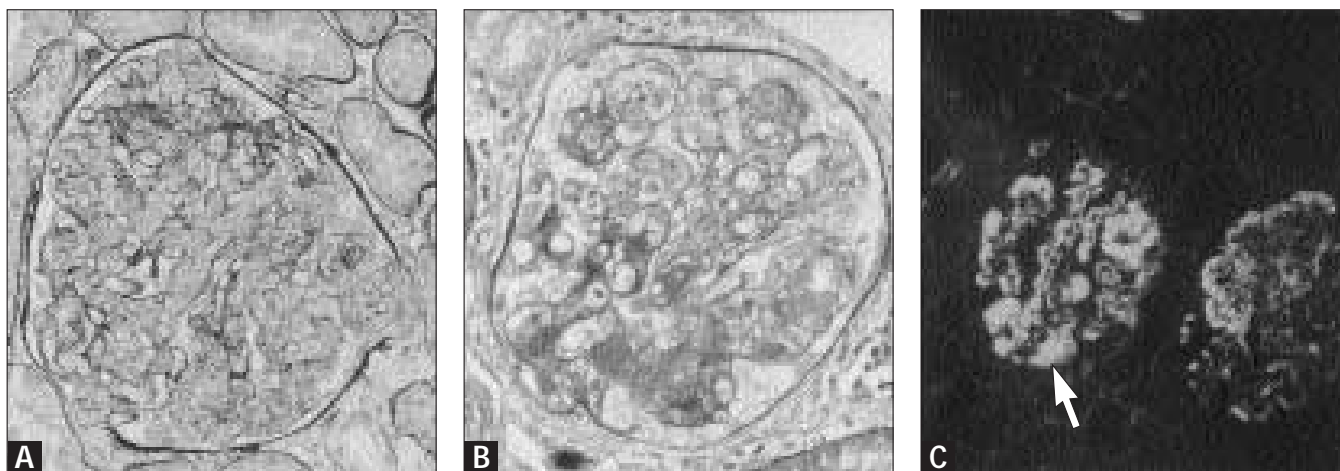
Glomerular deposition of immunoglobulin A- $\lambda$  paraproteins. No paraproteins or cryoglobulins could be found in the serum of this patient. In addition, the urinary excretion of light chains was not detectable. **A**, A mesangiocapillary pattern of injury with deposition of eosinophilic material in the capillary wall and mesangium. **B**, Immunofluorescence. The deposits were positive for  $\lambda$  light chains (and immunoglobulin A). **C**, Ultrastructurally, below the glomerular basement membrane, organized deposits composed of parallel arranged fibrils or gridlike structures can be seen. (*Panel A*, methenamine silver, original magnification  $\times 400$ ,  $\times 400$ ,  $\times 25,000$ , respectively.)



**FIGURE 11-41** (see Color Plate)

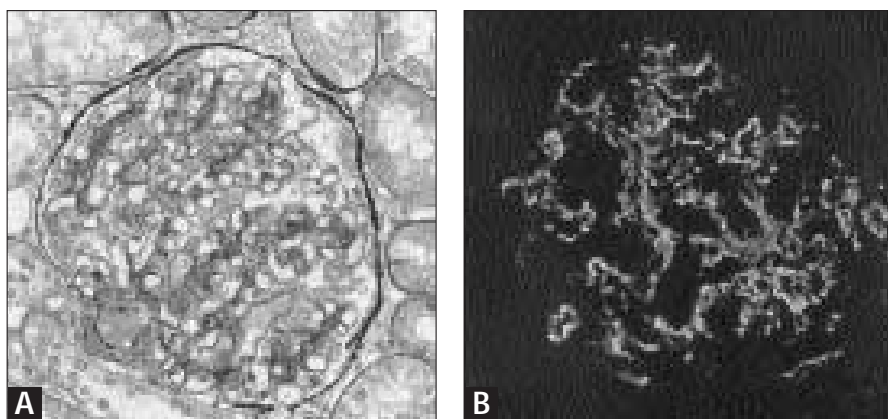
Glomerular deposition of immunoglobulin G- $\lambda$  in a patient with multiple myeloma. **A**, Glomerulus with many intracapillary protein thrombi. **B**, The material was composed of

closely packed tubules arranged in parallel. (*Panel A*, toluidine blue. Original magnification  $\times 600$ ,  $\times 130,000$ , respectively.)

**FIGURE 11-42**

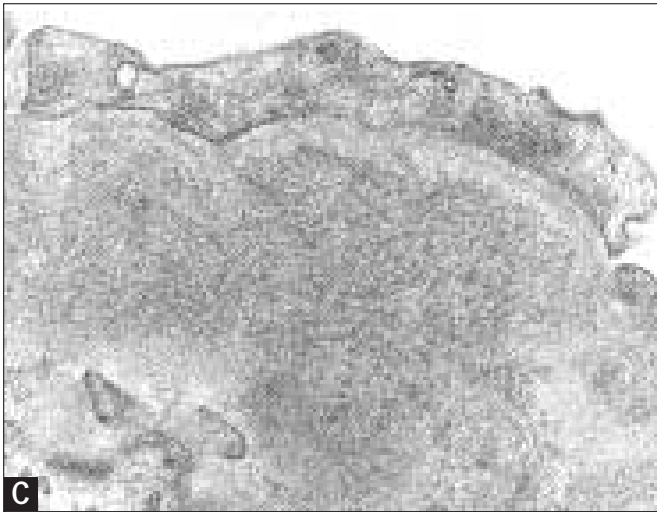
Mixed cryoglobulinemia. Of the three types of cryoglobulins, types I and II contain monoclonal immunoglobulins (Ig). Type I cryoglobulins occur in monoclonal gammopathies and lymphomas and consist of a single monoclonal immunoglobulin. Type II cryoglobulins (also called *mixed cryoglobulinemia*) occur in systemic infections, autoimmune diseases, and malignancies. Type II cryoglobulins consist of two components, a monoclonal immunoglobulin, most frequently IgM, with rheumatoid factor activity directed to the polyclonal IgG component. Various patterns of glomerular injury can be found, such as a diffuse endocapillary proliferative glomerulonephritis with a prominent influx of monocytes, or a mesangiocapillary glomerulonephritis. Less frequently, a diffuse mesangial proliferative, sclerosing glomerulonephritis, or both can be seen. Eosinophilic aggregates along the glomerular basement membrane (GBM) or in the lumina designated as *thrombi* frequently are present. Type II cryoglobulinemia is sometimes accompanied by a vasculitis. The aggregates in the glomeruli of type I, as seen on immunofluorescence, have a composition identical to that of the cryoglobulins in the serum. The deposits in type II contain IgG, IgM, and complement. Ultrastructurally, the deposits usually demonstrate an organized or crystalline appearance. In type I, the deposits frequently are organized in closely packed fibrils, long tubules, or crystals. In type II, short tubulo-annular structures can be found. Sometimes aggregates in the glomeruli composed of a single monoclonal immunoglobulin component can be demonstrated in patients without evidence of a monoclonal immunoglobulin or cryoglobulins in the serum.

**A**, Diffuse endocapillary proliferative glomerulonephritis with prominent influx of mononuclear cells. **B**, Mixed pattern of injury in a patient with Sjögren's syndrome. Intracapillary thrombi, increase of mesangial cells and matrix, and occasionally duplication of the GBM. **C**, Immunofluorescence with staining for IgM. **D**, Electron microscopy of tubular and annular structures in the glomerular deposits. (Parts **A**, **B**, methenamine silver. Original magnification  $\times 400$ ,  $\times 400$ ,  $\times 200$ ,  $\times 120,000$ , respectively.)

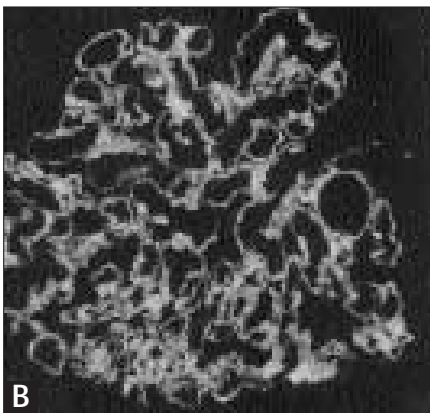
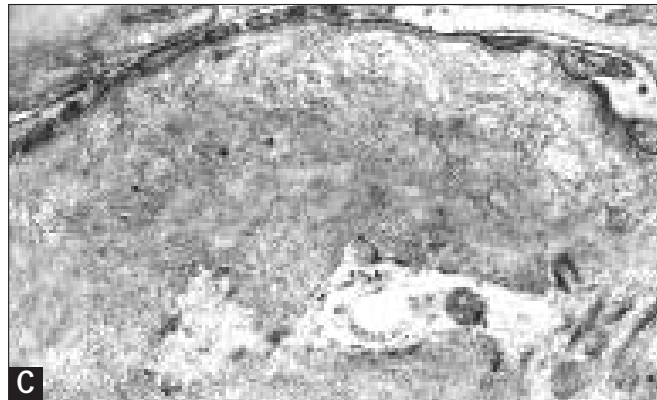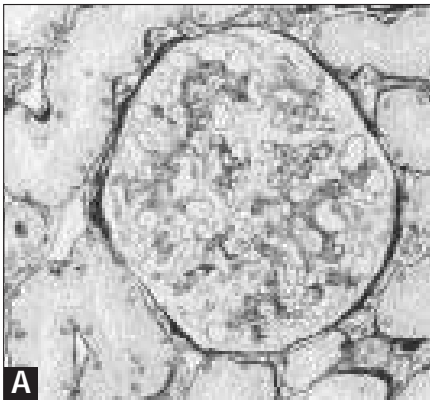
**FIGURE 11-43**

Biopsy specimen of immunotactoid glomerulonephritis with immunoglobulin A- $\lambda$  deposits. The patient had no signs of a monoclonal gammopathy or lymphoma. **A**, Mild increase of mesangial matrix with segmental irregularity of the capillary wall. **B**, Immunofluorescence. The deposits are positive for  $\lambda$  (and immunoglobulin A) **C**, Below the glomerular basement membrane, seen is an accumulation of short microtubules with a diameter of about 30 nm. (Part **A**, methenamine silver. Original magnification  $\times 400$ ,  $\times 400$ ,  $\times 25,000$ , respectively.)

(Continued on next page)

**FIGURE 11-43 (Continued)**

Immunotactoid and fibrillary glomerulonephritis are comprised of lesions characterized by the deposition of immunoglobulins (and complement) arranged in randomly distributed fibrils or microtubules in the capillary wall and mesangium [89,90]. These lesions are thicker than are amyloid fibrils and are negative on congo-red staining. Although presently it is not clear whether these forms of glomerulonephritis are different disease entities or are different morphologic expressions of one disease, some morphologic and clinical features exist that suggest fibrillary glomerulonephritis must be distinguished from immunotactoid glomerulonephritis [91]. Immunotactoid glomerulonephritis shows deposition of microtubules with diameters of 35 to 50 nm and commonly is associated with a lymphoproliferative disease. The deposited immunoglobulins frequently are of monoclonal composition. In contrast, fibrillary glomerulonephritis is characterized by fibrils with diameters of about 18 to 20 nm. The deposited immunoglobulins usually are polyclonal and very rarely monoclonal. An association with a lymphoproliferative disease is uncommon in contrast to immunotactoid glomerulonephritis.

**FIGURE 11-44**

Fibrillary glomerulonephritis. **A**, Moderate widening of mesangial areas by increase of matrix. **B**, Immunofluorescence. Heavy staining for IgG (and complement,  $\kappa$  and  $\lambda$  light chains). **C**, Ultrastructurally, randomly distributed long fibrils with diameters of 18 to 22 nm are localized in the capillary wall. (*Panel A*, methenamine silver. Original magnification  $\times 400$ ,  $\times 300$ ,  $\times 27,000$ , respectively.)

**CLINICAL PRESENTATION, FREQUENCY, AND CAUSES OF RENAL INVOLVEMENT IN DYSPROTEINEMIAS**

Acute deterioration of renal function (5–10%)  
 Dehydration  
 Hypercalcemia  
 Cast nephropathy  
 Crescentic glomerulonephritis  
 Chronic renal insufficiency (45–75%)  
 Myeloma cast nephropathy  
 Light chain (AL) amyloidosis  
 Interstitial plasma cell infiltration (rare)  
 Proteinuria-nephrotic syndrome (50–80%)  
 Light chain (AL) amyloidosis  
 Light chain deposition disease  
 Heavy chain deposition disease  
 Cryoglobulinemic glomerular lesions  
 Fanconi's syndrome (1%)  
 Secondary lesions (20–30%)  
 Pyelonephritis  
 Nephrocalcinosis  
 Hyperuricemic nephropathy

**FIGURE 11-45**

Renal involvement in dysproteinemias can lead to different clinical manifestations: acute renal failure; progressive deterioration of renal function; proteinuria, which very often is in the nephrotic range; or, seldom, Fanconi's syndrome. Furthermore, a number of secondary conditions may occur that can induce additional renal damage. Certain features are associated with particular clinical symptoms. The type of clinical lesion that develops is predominantly determined by the so-called nephrotoxic characteristics of the excreted light chains, as demonstrated by infusion of light chains into mice. These infusions led to the same type of renal lesion as in humans [79,80]. Some of these nephrotoxic factors are listed in Figure 11-43.

**RISK FACTORS FOR RENAL INVOLVEMENT IN DYSPROTEINEMIAS**

Factors enhancing amyloid formation  
 Unfolding of paraprotein  
 $\lambda$  Light chain  
 Factors enhancing cast nephropathy  
 High urinary excretion of light chains  
 Binding of light chain to Tamm-Horsfall protein (THP)  
 Iso-electric point of light chain  $\geq 5.1$  ? (enhances binding to anionic THP (pI:3.2)  
 Tendency to self-aggregation of light chains  
 $\kappa$  Light chain  
 High levels of acute-phase proteins  
 Resistance of light chain to urinary or macrophage-derived proteases  
 Factors enhancing monoclonal immunoglobulin deposition  
 $\kappa$  Light chain  
 Presence of hydrophobic aminoacids in CDR1 or CDR2 of  $V_L$ -chain  
 Deletion of CH1 domain Fc part immunoglobulin  
 Factors enhancing acute renal failure  
 Hypercalcemia (19–44%)\*  
 Dehydration (10–65%)  
 Urinary tract infection (8–44%)  
 Nephrotoxic drugs (aminoglycosides; nonsteroidal anti-inflammatory drugs) (0–26%)  
 Intravenous radio contrast media (0–11%)  
 Loop diuretics

\*Percentage of patients in which this factor contributed to the development of acute renal failure.

From Winearls [69]; with permission.

**FIGURE 11-46**

Factors reported in the literature to be associated with development of the different renal lesions in patients with myeloma are summarized. The amyloidogenic potential is enhanced by certain amino acids that promote unfolding of the light chain and by the  $\lambda$  isotype of the light chain. In amyloidosis, the variable regions of the light chains are deposited predominantly after metabolism by macrophages. A number of factors have been characterized that enhance the binding of light chains to Tamm-Horsfall protein (THP), which is a critical event in the development of cast nephropathy. In monoclonal immunoglobulin deposition diseases, the granular deposits are composed mainly of the constant regions of light (and seldom heavy) chains.

Hypercalcemia, which frequently occurs in patients with myeloma and results from increased interleukin-6-mediated bone resorption, can contribute to renal impairment by way of different mechanisms: dehydration (hyperremesis and nephrogenic diabetes insipidus), induction of nephrocalcinosis, and enhancement of light chain aggregation with THP. All other factors either diminish tubular flow or increase distal tubular sodium concentration, thereby again enhancing cast formation.

## TREATMENT OF RENAL LESIONS IN DYSPROTEINEMIAS

Renal therapy	Antitumor therapy
Preventive measures: Rehydration, forced diuresis (>3 L/24 h) Correction hypercalcemia Alkalinization of urine (pH ≥7) Cessation of nephrotoxic drugs Treatment of infections Colchicine ? Plasmapheresis in acute renal failure Recovery of renal function increases from 0–18% in the control group to 43–84% with plasmapheresis Dialysis 54% survival after 1 y, and 25% after 2 y Theoretically, PD could result in a better removal of light chains Renal transplantation Light chain amyloidosis: 29 patients; high nonrenal mortality rate, 30% recurrence rate Light chain deposition disease: 12 patients; 50% recurrence rate Cryoglobulinemia: 50% recurrence rate Multiple myeloma: 18 patients with low-grade disease; 8 alive, 5 succumbed to infection, and 5 to recurrence	Melphalan-prednisone First-line therapy: 45% remission rate  Vincristine-adriamycin-dexamethazone (VAD)* Second-line therapy: relapses, 40% remission; refractory cases, 25% remission  High-dose chemotherapy and bone marrow transplantation Relatively good results in patients without renal involvement. No data for patients with renal involvement

\*VAD protocol has the advantage that drug metabolism is independent of kidney function, whereas the melphalan dose must be adjusted to renal function.

FIGURE 11-47

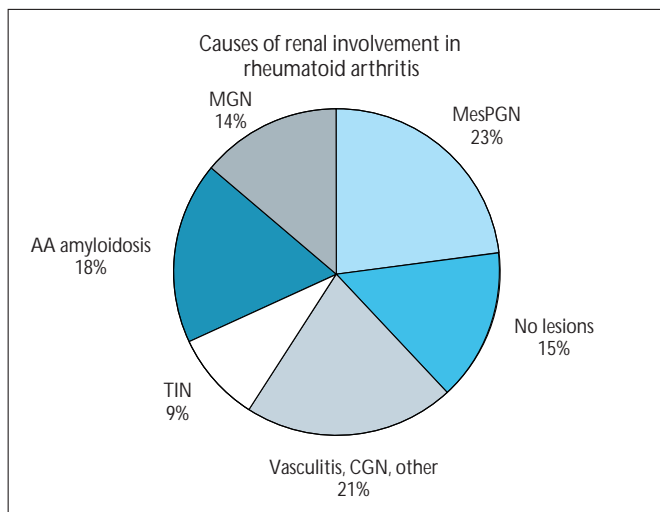
Treatment should be directed at ameliorating the renal lesion and reduction of the production of paraproteins. In patients with myeloma it is very important to prevent situations that could precipitate acute renal failure. In this respect, dehydration and hypercalcemia are very harmful. Measures should be taken to maintain a high fluid intake. When radiocontrast agents are necessary, hydration before the study decreases the chance of intratubular cast formation between light chains and the contrast agent. Alkalinization of the urine can reduce the interaction between light chains and Tamm-Horsfall protein (THP). Nephrotoxic drugs (such as nonsteroidal anti-inflammatory drugs and gentamycin) should not be used because they further enhance tubular dysfunction. Experimental studies suggest that colchicine may be helpful in reducing cast formation either by decreasing THP secretion or modifying the interaction between THP and light chains. Presently, no data exist that document the clinical efficacy of this treatment.

Plasmapheresis has the potential to remove the toxic light chains from the circulation, although in certain patients the serum concentration can be rather low. Plasmapheresis alone does not reduce the rate of production of the paraprotein; therefore, this treatment should be combined with chemotherapy. Patients with extensive cast formation and interstitial changes seem to respond less well to

plasmapheresis that do those without cast formation and interstitial changes [81]. Of two controlled studies, only one showed a beneficial effect of addition of plasmapheresis to chemotherapy [82,83]. The major determinant for success seems to be a good response to chemotherapy [83]. Furthermore, patients with extensive cast formation and interstitial changes seem to respond less well to chemotherapy than do those without cast formation and interstitial changes [81,83]. The patient with end-stage renal disease can be treated with dialysis, although survival is poor and dependent on the success of chemotherapy.

The experience of renal transplantation in patients with dysproteinemias is, for obvious reasons, rather limited. The results are rather disappointing with a high mortality rate, especially in patients with multiple myeloma and amyloidosis. Patients surviving for more than 1 year show a high recurrence rate [84–87]. Discussion of antitumor therapy is beyond the scope of this review. Briefly, treatment with melphalan and prednisone is considered to be the first choice, whereas more aggressive treatment with vincristine-adriamycin-dexamethasone is given to patients who do not respond to or who relapse after melphalan and prednisone therapy. Recently, more encouraging results have been obtained with ablative chemotherapy and stem-cell reinfusion [88]. PD—peritoneal dialysis.

## Renal Involvement in Rheumatic Diseases



**FIGURE 11-48**

**Causes of renal involvement in rheumatoid arthritis.** In rheumatoid arthritis, a variety of renal disorders may occur secondary to either the underlying disease or to drugs used to treat it. The most frequent abnormality is a mesangial proliferative glomerulonephritis (MesPGN) with, in most cases, only mesangial immunoglobulin M (IgM) and sometimes IgA and complement 3 (C3) deposits. IgG and C1q deposits are very rare. A correlation exists with the levels of rheumatoid factor; however, the underlying mechanism is unclear. Clinically, MPGN is characterized by hematuria and proteinuria.

Membranous glomerulopathy (MGN) in rheumatoid arthritis is mostly associated with gold or D-penicillamine treatment. MGN is seen more frequently in patients after therapy with D-penicillamine (7–14%) than after gold therapy (3–9%). When a patient

is positive for HLA-DR3 the risk for gold-induced MGN increases 10- to 30-fold and that for D-penicillamine increases 3- to 10-fold. Discontinuation of therapy leads to remission of the proteinuria-nephrotic syndrome in almost all cases, although it may be a year before complete recovery is achieved. MGN may occur in patients with rheumatoid arthritis not treated with gold or D-penicillamine. The mechanism for this is not clear.

Amyloidosis is associated with active joint disease. This type of amyloidosis is secondary to the deposition of the acute-phase reactant serum amyloid A (SAA) protein. This SAA is partly digested by macrophages and deposited in the tissues as AA amyloid. When a patient with active rheumatoid arthritis develops a nephrotic syndrome, AA amyloidosis is the most likely cause. No good treatment options exist for AA amyloidosis, other than treating the underlying disease. Renal transplantation in these patients is associated with a 3-year patient survival rate of 50% [92]. Especially in the early period after transplantation, there were high cardiovascular- and infection-related mortality rates. The rate of recurrence was approximately 20%.

The development of tubulointerstitial nephritis (TIN) in patients with rheumatoid arthritis is related to the prolonged use of analgesics, especially multicomponent analgesics and nonsteroidal anti-inflammatory drugs. A number of other renal conditions may develop in patients with rheumatoid arthritis. Vasculitis is associated with long-standing and nodular rheumatoid arthritis with high levels of rheumatoid factor. This condition may be associated with a crescentic glomerulonephritis (CGN) that, on immunofluorescence, is negative for immunoglobulin and complement deposits, as in Wegener's granulomatosis. The best treatment consists of cyclophosphamide and prednisone. References 93 and 94 provide more details on renal involvement in rheumatoid arthritis. Because the histologic abnormalities are not specific for rheumatoid arthritis, no histologic examples are given. They can be found elsewhere in this book. (*Data from Emery and Adu [94].*)

### RENAL MANIFESTATIONS IN SJÖGREN'S SYNDROME

Manifestation	%
Interstitial nephritis with or without tubular dysfunction	30–60
Tubular dysfunction (distal > proximal) associated with interstitial infiltrates and granuloma formation	20–25
Clinical symptoms:	
Type 1 renal tubular acidosis	
Fanconi's syndrome	
Nephrogenic diabetes insipidus	
Hypokalemia	
Glomerulonephritis	3–5
Mesangiocapillary glomerulonephritis	
Membranous glomerulonephritis	
Vasculitis	<5
Mostly extrarenal (skin, muscle, nerve); occasionally in the kidney	

**FIGURE 11-49**

The clinical manifestations of the tubulointerstitial nephritis in Sjögren's syndrome can vary and depend on localization of the functional impairment. Occasionally, symptoms of tubular dysfunction precede development of symptoms of Sjögren's syndrome. It is unclear what causes these tubular dysfunctions. When the degree of tubulointerstitial damage is not chronic, corticosteroids are beneficial. Glomerular involvement is rare in Sjögren's syndrome. When a glomerulonephritis is present, the patient should be evaluated for the presence of cryoglobulins and existence of systemic lupus erythematosus. Reference 95 provides a more detailed description of this subject.

## RENAL INVOLVEMENT IN SCLERODERMA

Incidence of renal involvement	Risk factors for renal crisis	Clinical characteristics of renal crisis	Therapy for renal crisis
Based on autopsy studies, 60–70%	Diffuse form of scleroderma	Acute onset	Prevention of reduction of renal perfusion (eg, dehydration, diuretics, cyclosporin A, nonsteroidal anti-inflammatory drugs)
Based on clinical symptoms, 30–50%	Rapid progression of skin lesions	Marked to severe (malignant) hypertension (10% of patients remain normotensive)	Angiotensin-converting enzyme inhibitors (even in patients with normotension)
Scleroderma renal crisis, 10–15%	HLA BW35, DR3, DR5	Features of malignant hypertension	Renal replacement therapy
	Race (Blacks > whites)	Micro-angiopathic hemolytic anemia and thrombopenia	
	Use of corticosteroids or cyclosporine A?	Mostly normal urinary sediment (in cases with malignant hypertension hematuria possible)	
	Cold exposure?	Progressive decline of renal function	

FIGURE 11-50

The main features of renal involvement in scleroderma are summarized. The major manifestation is the so-called renal crisis. Besides this often life-threatening manifestation, other patients may display milder forms of renal involvement, clinically characterized by mild proteinuria or slight deterioration of kidney function. Renal involvement is more common in patients with the diffuse form of scleroderma that is serologically characterized by antibodies against topoisomerase I or RNA polymerase III. Patients with progressive skin disease should be monitored carefully for hypertension and signs of renal involvement. Early institution of angiotensin-converting enzyme (ACE) inhibition in patients with micro-albuminuria can prevent further deterioration of kidney function [96,97]. ACE inhibition is also

the mainstay of treatment for patients with scleroderma renal crisis, because it will significantly reduce progression to renal failure, increase the chance of recovery if renal failure has already developed, and improve the 1-year patient survival rate. Renal replacement therapy (hemodialysis or continuous ambulatory peritoneal dialysis) should be offered to patients whose renal function does not recover. The patient survival rate, however, is lower than in patients with other collagen-vascular diseases such as lupus nephritis. Limited experience with renal transplantation indicates that successful transplantation is possible, especially in patients with quiescent disease. Recurrence in the transplanted kidney has been reported [84]. References 96 to 98 provide more extensive reviews on the subject.

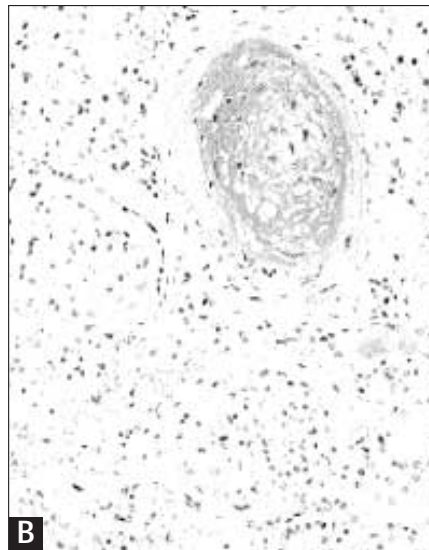
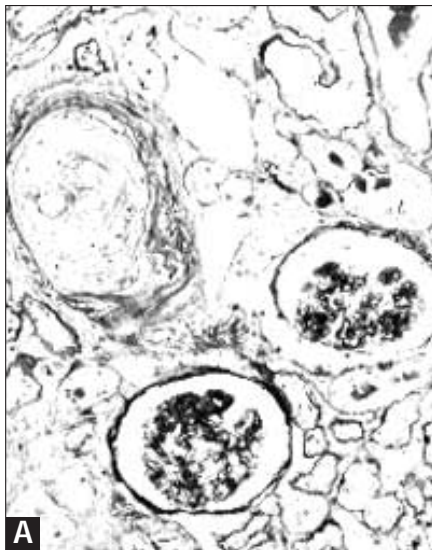
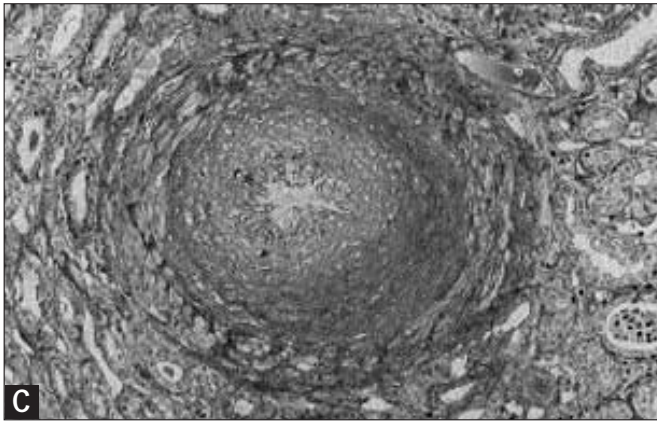


FIGURE 11-51

Scleroderma. In the acute phase, small- and medium-sized renal arteries show mucoid thickening of the intima with severe narrowing of the lumen. Sometimes these lesions are accompanied by thrombosis and fibrinoid necrosis of the arterioles and glomeruli. Morphologically, the vascular alterations resemble malignant nephrosclerosis (malignant hypertension) or hemolytic-uremic syndrome. In the chronic phase, the mucoid intimal material is replaced by fibrous tissue.

**A**, Severe narrowing of a small-sized renal artery owing to extensive endothelial widening with ischemia of glomeruli.  
**B**, Accumulation of mucopolysaccharide material in the widened endothelial layer.

(Continued on next page)



**FIGURE 11-51 (Continued)**

**C**, Severe intimal fibrosis of a medium-sized artery of a more chronic phase of scleroderma. (*Panel A*, methenamine silver, original magnification  $\times 100$ . *Panel B*, alcian blue stain, original magnification  $\times 100$ . *Panel C*, cellulose acetate butyrate stain, original magnification  $\times 150$ .)

## References

1. Tan EM, Cohen AS, Fries JF, *et al.*: The 1982 revised criteria for the classification of systemic lupus erythematosus. *Arthritis Rheumatol* 1982, 25:1271–1277.
2. Maddison PJ: Systemic lupus erythematosus variants. In *Slide Atlas of Rheumatology*. Edited by Dieppe PA, Bacon PA, Bamji AN, Watt I. London: Gower; 1984:9.1–9.14.
3. Aarden LA, De Groot ER, Feltkamp TEW: Immunology of DNA. III. *Crithidia luciliae*: a simple substrate for the detection of anti-dsDNA with the immunofluorescence technique. *Ann NY Acad Sci* 1975, 254:505–509.
4. Smeenk RJT, Berden JHM, Swaak AJG: dsDNA autoantibodies. In *Autoantibodies*. Edited by Peter JB, Shoenfeld Y. Amsterdam: Elsevier; 1996:227–236.
5. Klippel JH, Croft JD: Systemic lupus erythematosus. In *Slide Atlas of Rheumatology*. Edited by Dieppe PA, Bacon PA, Bamji AN, Watt I. London: Gower; 1984:8.1–8.14.
6. ter Borg EJ, Horst G, Hummel EJ, *et al.*: Predictive value of rises in anti-double-stranded DNA antibody levels for disease exacerbations in systemic lupus erythematosus: a long term prospective study. *Arthritis Rheumatol* 1990, 33:634–643.
7. Verheyen R, Salden M, Van Venrooij WJ: Protein blotting. In *Manual of Biological Markers of Disease*. Edited by van Venrooij WJ, Maini RN. Dordrecht: Kluwer; 1997:A4.1–A4.25.
8. Van Venrooij WJ, De Rooij DJ, van de Putte LBA, Habets WJ: De serologische herkenning van gedefinieerde kernantigenen bij collageenziekten: immunoblotting als nieuw diagnostisch middel. *Ned Tijdschr Geneesk* 1985, 129:1124–1129.
9. Watanabe-Fukunaga R, Brannan CI, Copeland NG, *et al.*: Lymphoproliferation disorder in mice explained by defects in Fas antigen that mediates apoptosis. *Nature* 1992, 356:314–317.
10. Singer GG, Carrera AC, Marshak-Rothstein A, *et al.*: Apoptosis, Fas and systemic autoimmunity: the MRL/lpr model. *Curr Opin Immunol* 1994, 6:913–920.
11. Tax WJM, Kramers C, van Bruggen MCJ, Berden JHM: Apoptosis, nucleosomes, and nephritis in systemic lupus erythematosus. *Kidney Int* 1995, 48:666–673.
12. Berden JHM: Systemic lupus erythematosus: disturbed apoptosis? *Ned Tijdschr Geneesk* 1997, 141:1848–1854.
13. Rumore PM, Steinman CR: Endogenous circulating DNA in systemic lupus erythematosus. Occurrence as multimeric complexes bound to histone. *J Clin Invest* 1990, 86:69–74.
14. Berden JHM: Lupus nephritis. *Nephrology Forum. Kidney Int* 1997, 52:538–558.
15. Mohan C, Adams S, Stanik V, Datta SK: Nucleosome, a major immunogen for pathogenic autoantibody-inducing T cells of lupus. *J Exp Med* 1993, 177:1367–1381.
16. Kaliyaperumal A, Mohan C, Wu W, Datta SK: Nucleosomal peptide epitopes for nephritis-inducing T helper cells of murine lupus. *J Exp Med* 1996, 183:2459–2469.
17. Burlingame RW, Rubin RL, Balderas RS, Theofilopoulos AN: Genesis and evolution of anti-chromatin autoantibodies in murine lupus implicates T-dependent immunization with self antigen. *J Clin Invest* 1993, 91:1687–1696.
18. Amoura Z, Chabre H, Koutouzov S, *et al.*: Nucleosome-restricted antibodies are detected before anti-dsDNA and/or antihistone antibodies in serum of MRL-Mp lpr/lpr and +/+ mice, and are present in kidney eluates of lupus mice with proteinuria. *Arthritis Rheumatol* 1994, 37:1684–1688.
19. Burlingame RW, Boey ML, Starkebaum G, Rubin RL: The central role of chromatin in autoimmune responses to histones and DNA in systemic lupus erythematosus. *J Clin Invest* 1994, 94:184–192.
20. Chabre H, Amoura Z, Piette JC, *et al.*: Presence of nucleosome-restricted antibodies in patients with systemic lupus erythematosus. *Arthritis Rheumatol* 1995, 38:1485–1491.
21. Kramers C, Hylkema MN, van Bruggen MCJ, *et al.*: Anti-nucleosome antibodies complexed to nucleosomal antigens show anti-DNA reactivity and bind to rat glomerular basement membrane *in vivo*. *J Clin Invest* 1994, 94:568–577.
22. van Bruggen MCJ, Kramers C, Hylkema MN, *et al.*: Significance of anti-nuclear and anti-extra cellular matrix auto-antibodies for albuminuria in MRL/l mice. A longitudinal study on plasma and glomerular eluates. *Clin Exp Immunol* 1996, 105:132–139.
23. van Bruggen MCJ, Kramers C, Walgreen B, *et al.*: Nucleosomes and histones are present in glomerular deposits in human lupus nephritis. *Nephrol Dial Transplant* 1997, 12:57–66.
24. van den Born J, van den Heuvel LPWJ, Bakker MAH, *et al.*: Distribution of GBM heparan sulphate proteoglycan core protein and side chains in human glomerular diseases. *Kidney Int* 1993, 43:454–463.
25. van Bruggen MCJ, Kramers C, Hylkema MN, *et al.*: Decrease of heparan sulfate staining in the glomerular basement membrane in murine lupus nephritis. *Am J Pathol* 1995, 146:753–763.
26. van Bruggen MCJ, Walgreen B, Rijkers GPM, *et al.*: Heparin and heparinoids prevent the binding of immune complexes containing nucleosomal antigens to the GBM and delay nephritis in MRL/l mice. *Kidney Int* 1996, 50:1555–1564.

27. Strasser A, Whittingham S, Vaux DL, *et al.*: Enforced bcl-2 expression in B-lymphoid cells prolongs antibody responses and exhibits autoimmune diseases. *Proc Natl Acad Sci USA* 1991, 88:8661-8665.
28. Mysler E, Bini P, Drappa J, *et al.*: The apoptosis-1/Fas protein in human systemic lupus erythematosus. *J Clin Invest* 1994, 93:1029-1034.
29. Lorenz H, Gruenke M, Hieronymus T, *et al.*: *In vitro* apoptosis and expression of apoptosis related molecules in lymphocytes from patients with systemic lupus erythematosus and other autoimmune diseases. *Arthritis Rheumatol* 1997, 40:306-317.
30. Cheng J, Zhou T, Liu C, *et al.*: Protection from Fas-mediated apoptosis by a soluble form of the Fas molecule. *Science* 1994, 263:1759-1762.
31. Goel N, Ulrich DT, St.Clair EW, *et al.*: Lack of correlation between serum soluble Fas/APO-1 levels and autoimmune disease. *Arthritis Rheumatol* 1995, 38:1738-1743.
32. Knipping E, Krammer PH, Onel KB, *et al.*: Levels of soluble Fas/APO-1/CD95 in systemic lupus erythematosus and juvenile rheumatoid arthritis. *Arthritis Rheumatol* 1995, 38:1735-1737.
33. Emlen W, Niebur J, Kadera R: Accelerated *in vitro* apoptosis of lymphocytes from patients with systemic lupus erythematosus. *J Immunol* 1994, 152:3685-3692.
34. Kovacs B, Vassilopoulos D, Vogelgesang SA, Tsokos GC: Defective CD3-mediated cell death in activated T cells from patients with systemic lupus erythematosus: role of decreased intracellular TNF- $\alpha$ . *Clin Immunol Immunopathol* 1996, 81:293-302.
35. Casciola-Rosen LA, Anhalt G, Rosen A: DNA-dependent protein kinase is one of a subset of autoantigens specifically cleaved early during apoptosis. *J Exp Med* 1995, 182:1625-1634.
36. Casiano CA, Martin SJ, Green DR, Tan EM: Selective cleavage of nuclear autoantigens during CD95(Fas/APO-1)-mediated T cell apoptosis. *J Exp Med* 1996, 183:765-770.
37. Rosen A, Casciola-Rosen LA: Macromolecular substrates for the ICE-like proteases during apoptosis. *J Cell Biochem* 1997, 64:50-54.
38. Casiano C, Tan EM: Recent developments in the understanding of anti-nuclear autoantibodies. *Int Arch Allergy Immunol* 1996, 111:308-313.
39. Utz P, Hottelet M, Schur PH, Anderson P: Proteins phosphorylated during stress-induced apoptosis are common targets for autoantibody production in patients with systemic lupus erythematosus. *J Exp Med* 1997, 185:843-854.
40. Cooke MS, Mistry N, Wood C, *et al.*: Immunogenicity of DNA damaged by reactive oxygen species. Implications for anti-DNA antibodies in lupus. *Free Rad Bio Med* 1997, 22:151-159.
41. Casciola-Rosen LA, Anhalt G, Rosen A: Autoantigens targeted in systemic lupus erythematosus are clustered in two populations of surface structures on apoptotic keratinocytes. *J Exp Med* 1994, 179:1317-1330.
42. Jordan P, Kuebler D: Autoimmune diseases: nuclear autoantigens can be found at the cell surface. *Mol Biol Rep* 1996, 22:63-66.
43. Hermann M, Voll RE, Zoller RM, *et al.*: Impaired phagocytosis of apoptotic cell material by monocyte-derived macrophages from patients with systemic lupus erythematosus. *Arthritis Rheum* 1998, 41:1241-1250.
44. Mamula MJ: Lupus autoimmunity: from peptides to particles. *Immunol Rev* 1995, 144:301-314.
45. Datta SK, Kaliyaperumal A: Nucleosome-driven autoimmune response in lupus. Pathogenic T helper cell epitopes and co-stimulatory signals. In *B Lymphocytes and Autoimmunity*. Edited by Chiorazzi N, Lahita RG, Pavelka K, Ferrarini M. New York: New York Academy of Sciences; 1997:155-170.
46. Churg J, Sobin LH: Lupus nephritis. In *Renal Diseases. Classification and Atlas of Glomerular Diseases*. Edited by Churg J. Tokyo: Igaku-Shoin; 1982:127-149.
47. Churg J, Bernstein J, Glassock RJ: Lupus nephritis. In *Renal Diseases. Classification and Atlas of Glomerular Diseases*, edn 2. Edited by Churg J, Bernstein J, Glassock RJ. New York: Igaku-Shoin; 1995:151-180.
48. D'Agati VD: Systemic lupus erythematosus. In *Renal Biopsy Interpretation*. Edited by Silva FG, D'Agati VD, Nadasdy T. New York: Churchill Livingstone; 1996:181-220.
49. Austin III HA, Muenz LR, Joyce KM, *et al.*: Diffuse proliferative lupus nephritis: identification of specific pathologic features affecting renal outcome. *Kidney Int* 1984, 25:689-695.
50. Appel GB, Silva FG, Pirani CL, *et al.*: Renal involvement in systemic lupus erythematosus. *Medicine* 1975, 57:371-410.
51. Sloan RP, Schwartz MM, Korbet SM, Borok RZ, and the Lupus Nephritis Collaborative Study Group: Long-term outcome in systemic lupus erythematosus membranous glomerulonephritis. *J Am Soc Nephrol* 1996, 7:299-305.
52. Bruns FJ, Adler S, Fraley DS, Segel DP: Sustained remission of membranous glomerulonephritis after cyclophosphamide and prednisone. *Ann Intern Med* 1991, 114:725-730.
53. Reichert LJM, Huysmans FTM, Assmann KJM, *et al.*: Preserving renal function in patients with membranous nephropathy: daily oral chlorambucil compared with intermittent monthly pulses of cyclophosphamide. *Ann Intern Med* 1994, 121:328-333.
54. Falk RJ, Hogan SL, Muller KE, Jenette C, and the Glomerular Disease Collaborative Network: Treatment of progressive membranous glomerulopathy. A randomized trial comparing cyclophosphamide and corticosteroids with corticosteroids alone. *Ann Intern Med* 1992, 116:438-445.
55. Appel GB, Valeri A: The course and treatment of lupus nephritis. *Ann Rev Med* 1994, 45:525-537.
56. Austin III HA, Klippel JH, Balow JE, *et al.*: Therapy of lupus nephritis. Controlled trial of prednisone and cytotoxic drugs. *N Engl J Med* 1986, 314:614-619.
57. Cameron JS: What is the role of long-term cytotoxic agents in the treatment of lupus nephritis? *J Nephrol* 1993, 6:172-176.
58. Balow JE, Austin III HA, Muenz LR, *et al.*: Effect of treatment of the evolution of renal abnormalities in lupus nephritis. *N Engl J Med* 1984, 311:491-495.
59. Steinberg AD, Steinberg SC: Longterm preservation of renal function in patients with lupus nephritis receiving treatment that includes cyclophosphamide versus those treated with prednisone only. *Arthritis Rheumatol* 1991, 34:945-950.
60. Esdaile JM, Levinton C, Federgreen W, *et al.*: The clinical and renal biopsy predictors of long term outcome in lupus nephritis. *Q J Med* 1989, 72:779-833.
61. Ponticelli C, Zucchelli P, Moroni G, *et al.*: Long-term prognosis of diffuse lupus nephritis. *Clin Nephrol* 1987, 28:263-271.
62. Cameron JS, Turner BR, Ogg CS, *et al.*: Systemic lupus with nephritis: a long term study. *Q J Med* 1979, 48:1-24.
63. Bansal VK, Beto JA: Treatment of lupus nephritis: a meta-analysis of clinical trials. *Am J Kidney Dis* 1997, 29:193-199.
64. Nossent HC, Henzen-Logmans SC, Vroom TM, *et al.*: Contribution of renal biopsy data in predicting outcome in lupus nephritis. *Arthritis Rheumatol* 1990, 33:970-977.
65. Nossent JC, Swaak AJG, Berden JHM: Systemic lupus erythematosus: analysis of disease activity in 55 patients with end stage renal failure treated with hemodialysis or continuous ambulatory peritoneal dialysis. *Am J Med* 1990, 89:169-174.
66. Bombardier C, Gladman DD, Urowitz MB, *et al.*: Derivation of the SLEDAI. A disease activity index for lupus patients. Committee on Prognosis Studies in SLE. *Arthritis Rheumatol* 1992, 35:630-640.
67. Nossent JC: End stage renal disease in patients with systemic lupus erythematosus. In *Lupus Nephritis*. Edited by Lewis EJ. Oxford: Oxford University Press; 1998: in press.
68. Nossent JC, Swaak AJG, Berden JHM: Systemic lupus erythematosus after renal transplantation: patient and graft survival and disease activity. *Ann Intern Med* 1991, 114:183-188.
69. Winearls CG: Acute myeloma kidney. Nephrology Forum. *Kidney Int* 1995, 48:1347-1361.
70. Kyle RA: Multiple myeloma. Review of 869 cases. *Mayo Clin Proc* 1975, 50:29-40.
71. Alexanian R, Barlogie B, Dixon D: Renal failure in multiple myeloma. Pathogenesis and prognostic implications. *Arch Int Med* 1990, 150:1693-1695.

72. Pruzanski W: Clinical manifestations of multiple myeloma: relation to class and type of the M component. *Can Med Assoc J* 1976, 114:896–897.
73. Gallo G, Kumar V: Hematopoietic disorders. In *Renal Biopsy Interpretation*. Edited by Silva FG, D'Agati VD, Nadasdy T. New York: Churchill Livingstone; 1996:259–282.
74. Enlitz M, Weiss DT, Solomon A: Immunoglobulin heavy-chain-associated amyloidosis. *Proc Natl Acad Sci USA* 1990, 87:6542–6546.
75. Preudhomme JL, Aucouturier P, Touchard G, et al.: Monoclonal immunoglobulin deposition disease (Randall type). Relationship with structural abnormalities of immunoglobulin chains. *Kidney Int* 1994, 46:965–972.
76. Sanders PW, Herrera GA: Monoclonal immunoglobulin light chain-related renal diseases. *Semin Nephrol* 1993, 13:324–341.
77. Buxbaum JN, Chuba JV, Hellman GC, et al.: Monoclonal immunoglobulin deposition disease: light chain and light and heavy chain deposition diseases and their relation to light chain amyloidosis: clinical features, immunopathology, and molecular analyses. *Ann Intern Med* 1990, 112:455–464.
78. Autocouterier P, Khamlichi AA, Touchard G, et al.: Brief report: heavy-chain deposition disease. *Nucl Acids Res* 1993, 329:1389–1393.
79. Solomon A, Weiss DT, Kattine AA: Nephrotoxic potential of Bence Jones proteins. *N Engl J Med* 1991, 324:1845–1851.
80. Sanders PW, Booker BB: Pathobiology of cast nephropathy from human Bence Jones proteins. *J Clin Invest* 1992, 89:630–639.
81. Johnson WJ, Kyle RA, Pineda AA, et al.: Treatment of renal failure associated with multiple myeloma. Plasmapheresis, hemodialysis and chemotherapy. *Arch Intern Med* 1990, 150:863–869.
82. Zucchelli P, Pasquali S, Cagnoli L, Ferrari G: Controlled plasma exchange trial in acute renal failure due to multiple myeloma. *Kidney Int* 1988, 33:1175–1180.
83. Misiani R, Tiraboschi G, Mingardi G, Mecca G: Management of myeloma kidney: an anti-light chain approach. *Am J Kidney Dis* 1987, 10:28–33.
84. Ramos EL, Tisher CC: Recurrent disease in the kidney transplant. *Am J Kidney Dis* 1994, 24:142–154.
85. Harrison KL, Alpers CE, Davis CL: *De novo* amyloidosis in a renal allograft: a case report and review of the literature. *Am J Kidney Dis* 1993, 22:468–476.
86. Sammett D, Dagher F, Abbi R, et al.: Renal transplantation in multiple myeloma. *Transplantation* 1996, 62:1577–1580.
87. Gerlag PGG, Koene RAP, Berden JHM: Renal transplantation in light chain nephropathy: case report and review of the literature. *Clin Nephrol* 1986, 25:101–104.
88. Varet B, Choukroun G, Grunfeld JP: Multiple myeloma. Part II: treatment. *Nephron* 1995, 70:18–20.
89. Iskander SS, Falk RJ, Jenette JC: Clinical and pathologic features of fibrillary glomerulonephritis. *Kidney Int* 1992, 42:1401–1407.
90. Fogo A, Qureshi N, Horn RG: Morphologic and clinical features of fibrillary versus immunotactoid glomerulonephritis. *Am J Kidney Dis* 1993, 22:367–377.
91. Alpers CE: Fibrillary glomerulonephritis and immunotactoid glomerulopathy. *Curr Opin Nephrol Hyperts* 1994, 3:349–355.
92. Pasternack A, Ahonen J, Kuhlback B: Renal transplantation in 45 patients with amyloidosis. *Transplantation* 1986, 42:598–601.
93. Helin H, Korpela M, Mustonen J, Pasternack A: Rheumatoid arthritis and ankylosing spondylitis. In *The Kidney in Collagen-Vascular Diseases*. Edited by Grishman E, Churg J, Needle MA, Venkateshan VS. New York: Raven Press; 1993:149–166.
94. Emery P, Adu D: The patient with rheumatoid arthritis, mixed connective tissue disease or polymyositis. In *Oxford Textbook of Clinical Nephrology*, edn 2. Edited by Davison AM, Cameron JS, Grunfeld JP, et al. Oxford: Oxford University Press; 1998:975–993.
95. Winer RL: Sjögren's syndrome. In *The Kidney in Collagen-Vascular Diseases*. Edited by Grishman E, Churg J, Needle MA, Venkateshan VS. New York: Raven Press; 1993:179–187.
96. Donohue JF: Scleroderma and the kidney. *Kidney Int* 1992, 41:462–477.
97. Steen VD: Scleroderma renal crisis. *Rheumatol Dis Clin North Am* 1996, 22:861–878.
98. D'Agati VD, Cannon PJ: Scleroderma (systemic sclerosis). In *The Kidney in Collagen-Vascular Diseases*. Edited by Grishman E, Churg J, Needle MA, Venkateshan VS. New York: Raven Press; 1993:121–147.