

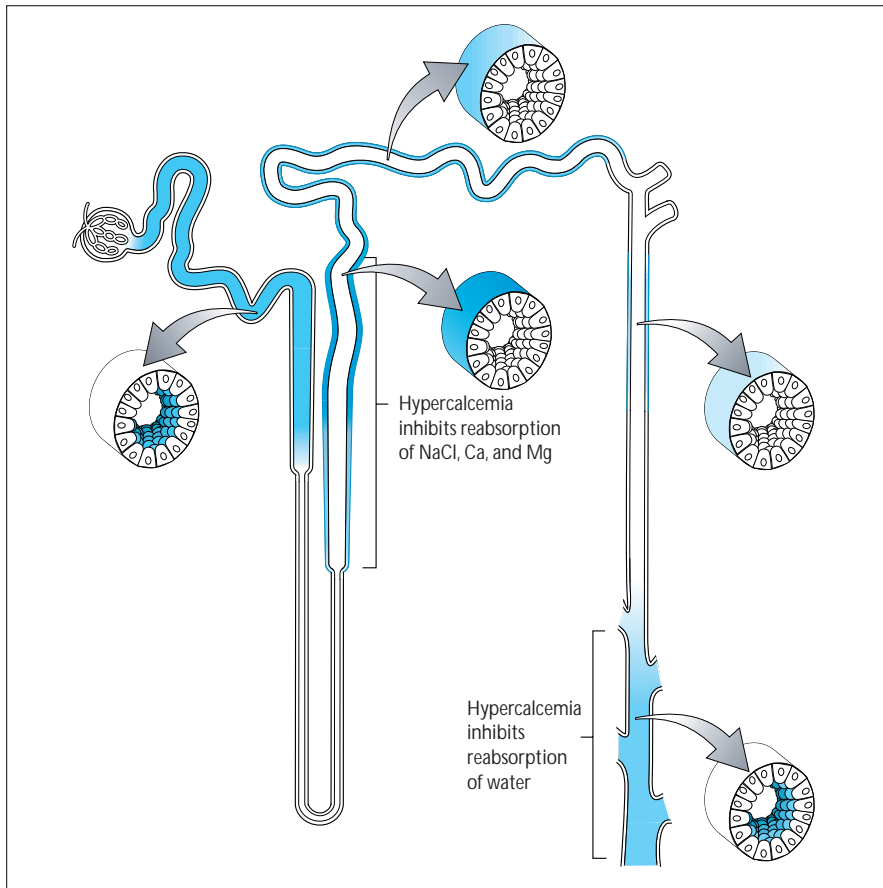
Metabolic Causes of Tubulointerstitial Disease

Steven J. Scheinman

A variety of metabolic conditions produce disease of the renal interstitium and tubular epithelium. In many cases, disease reflects the unique functional features of the nephron, in which the ionic composition, pH, and concentration of both the tubular and interstitial fluid range widely beyond the narrow confines seen in other tissues. Recent genetic discoveries have offered new insights into the molecular basis of some of these conditions, and have raised new questions. This chapter discusses nephrocalcinosis, the relatively nonspecific result of a variety of hypercalcemic and hypercalciuric states, as well as the renal consequences of hyperoxaluria, hypokalemia, and hyperuricemia.

CHAPTER

11

**FIGURE 11-1**

The recent discovery of the calcium-sensing receptor and increased understanding of its expression along the nephron have provided explanations for many of the known effects of hypercalcemia to cause clinical disturbances in renal tubular function [1]. In the parathyroid gland the calcium-sensing receptor allows the cell to sense extracellular levels of calcium and transduce that signal to regulate parathyroid hormone production and release. In the nephron, expression of the calcium receptor can be detected on the apical surface of cells of the papillary collecting duct, where calcium inhibits antidiuretic hormone action. Thus, hypercalcemia impairs urinary concentration and leads to isotonic polyuria. The most intense expression of the calcium receptor is in the thick ascending limb of the loop of Henle, particularly the cortical portion, where the calcium receptor protein is located on the basolateral side of the cells; this explains the known effects of hypercalcemia in inhibiting reabsorption of calcium, magnesium, and sodium chloride in the thick ascending limb [2]. In addition, hypercalcemia causes hypercalciuria through an increased filtered calcium load and suppression of parathyroid hormone release with a consequent reduction in calcium reabsorption. Ca—calcium; Mg—magnesium; NaCl—sodium chloride.

RENAL EFFECTS OF CALCIUM

Hypercalcemia

Collecting duct

Resistance to vasopressin, leading to isotonic polyuria

Thick ascending limb of the loop of Henle

Impaired sodium chloride reabsorption, leading to modest salt wasting

Inhibition of calcium transport, leading to hypercalciuria

Inhibition of magnesium transport, leading to hypomagnesemia

Renal vasculature

Arteriolar vasoconstriction

Reduction in ultrafiltration coefficient

Hypercalciuria

Microscopic hematuria

Nephrocalcinosis

Impaired urinary acidification

FIGURE 11-2

Hypercalcemia leads to renal vasoconstriction and a reduction in the glomerular filtration rate. However, no expression of the calcium-sensing receptor has been reported so far in renal vascular or glomerular tissue. Calcium receptor expression is present in the proximal convoluted tubule, on the basolateral side of cells of the distal convoluted tubule, and on the basolateral side of macula densa cells. Functional correlates of calcium receptor expression at these sites are not yet clear [3].

Hypercalciuria leads to microscopic hematuria and, in fact, is the most common cause of microscopic hematuria in children. The mechanism is presumed to involve microcrystallization of calcium salts in the tubular lumen. Conflicting effects of calcium on urinary acidification have been reported in clinical settings in which other factors, such as parathyroid hormone levels, may explain the observations. Whether or not it is the result of renal tubular acidosis, Nephrocalcinosis often is associated with impaired urinary acidification, whether or not it is the result of renal tubular acidosis.

CAUSES OF NEPHROCALCINOSIS

Medullary (total)	97.6
Primary hyperparathyroidism	32.4
Distal renal tubular acidosis	19.5
Medullary sponge kidney	11.3
Idiopathic hypercalciuria	5.9
Dent's disease	4.3
Milk-alkali syndrome	3.2
Oxalosis	3.2
Hypomagnesemia-hypercalciuria	1.6
Sarcoidosis	1.6
Renal papillary necrosis	1.6
Hypervitaminosis D	1.6
Other*	4.0
Undiscovered causes	6.7
Cortical (total)	2.4

Adapted from Wrong [3]; with permission.

* Other causes include Bartter syndrome, idiopathic Fanconi syndrome, hypothyroidism, and severe acute tubular necrosis.

FIGURE 11-3

Nephrocalcinosis represents calcification of the renal parenchyma. It is primarily medullary in most cases except in dystrophic calcification associated with inflammatory, toxic, or ischemic disease. Nephrocalcinosis can be seen in association with chronic or severe hypercalcemia or in a variety of hypercalciuric states. The spectrum of causes of nephrocalcinosis is described by Wrong [3]. The numbers represent the percentage of the total of 375 patients. It is likely that the case mix is affected to some extent by Wrong's interests in, *eg*, renal tubular acidosis (RTA) and Dent's disease, but this is by far the largest published series. As in other studies, the most important causes of nephrocalcinosis are primary hyperparathyroidism, distal RTA, and medullary sponge kidney. The primary factor predisposing patients to renal calcification in many of these conditions is hypercalciuria, as occurs in idiopathic hypercalciuria, Dent's disease, milk-alkali syndrome, sarcoidosis, hypervitaminosis D, and often in distal RTA. In distal RTA and milk-alkali syndrome, relative or absolute urinary alkalinity promote precipitation of calcium phosphate crystals in the tubular lumina, and hypocitraturia is an important contributing factor in distal RTA. Causes of cortical nephrocalcinosis in this study included acute cortical necrosis, chronic glomerulonephritis, and chronic pyelonephritis.

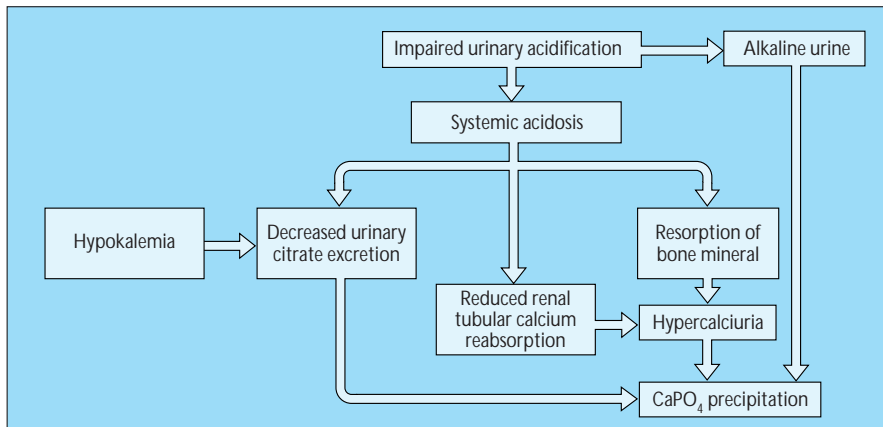
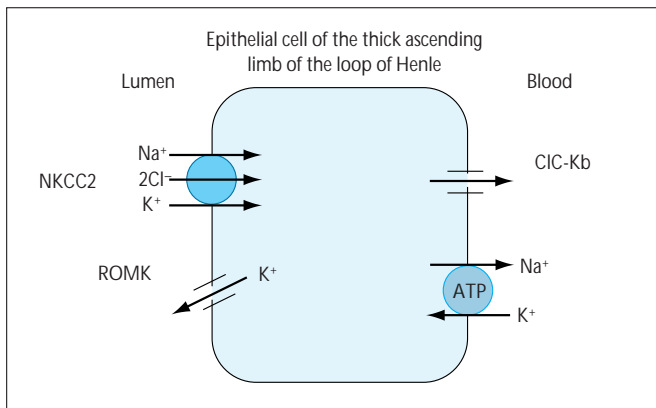


FIGURE 11-4

Nephrocalcinosis in type I (distal) renal tubular acidosis. Nephrocalcinosis and nephrolithiasis are common complications in distal renal tubular acidosis (RTA-1). Several factors contribute to the pathogenesis. The most important of these factors are a reduction in urinary excretion of citrate and a persistently alkaline urine. Citrate inhibits the growth of calcium stones; its excretion is reduced in RTA-1 as a result of

both systemic acidosis and hypokalemia. The high urine pH favors precipitation of calcium phosphate (CaPO_4). Thus, RTA-1 should be suspected in any patient with pure calcium phosphate stones [4]. Systemic acidosis also promotes hypercalciuria, although not all patients with RTA-1 have excessive urinary calcium excretion [5]. Hypercalciuria results from resorption of bone mineral and the consequent increased filtered load of calcium as acidosis leads to consumption of bone buffers. Acidosis also has a direct effect of inhibiting renal tubular calcium reabsorption. Conversely, nephrocalcinosis from other causes can impair urinary acidification and lead to RTA in some patients. The mainstay of therapy for RTA-1 is potassium citrate, which corrects acidosis, replaces potassium, restores urinary citrate excretion, and reduces urinary loss of calcium [5]. (From Buckalew [5]; with permission.)

**FIGURE 11-5**

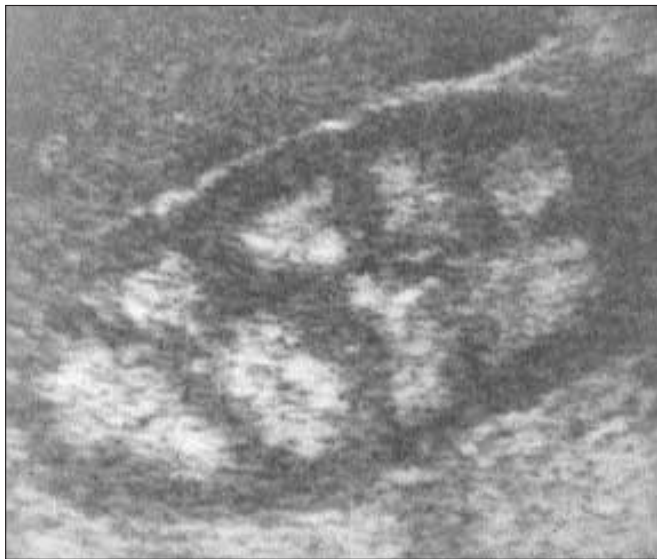Bartter syndrome. Bartter syndrome is a hereditary renal functional disorder characterized by hypokalemic metabolic alkalosis, renal salt wasting with normal or low blood pressure, polyuria, and hypercalciuria. Other features include juxtaglomerular hyperplasia, secondary hyperreninemia and hyperaldosteronism, and excessive urinary excretion of prostaglandin E. It often has been noted that patients with Bartter syndrome appear as if they were chronically exposed to loop diuretics; in fact, the major differential diagnosis is with diuretic abuse. Bartter syndrome often presents with growth retardation in children, and nephrocalcinosis is common. Bartter syndrome is inherited as an autosomal recessive trait.

The speculation that this syndrome could be explained by impaired reabsorption in the loop of Henle has now been confirmed by molecular studies. R.P. Lifton's group [6–8] identified loss-of-function mutations in three genes encoding different proteins, each

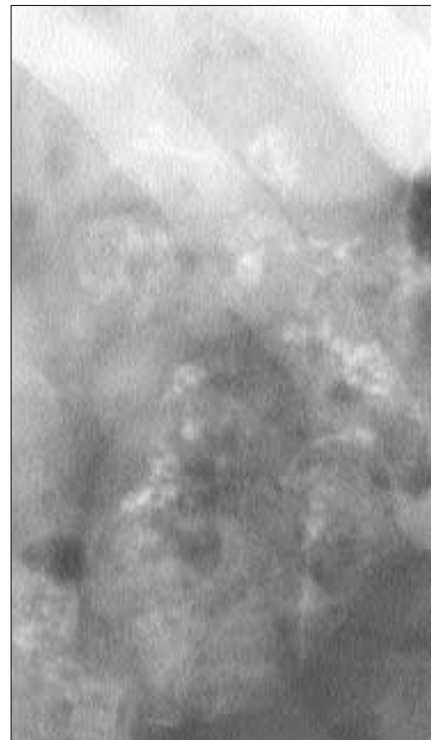
involved in the coordinated transport of salt in the thick ascending limb of the loop of Henle. In this nephron segment, sodium chloride is transported into the cell together with potassium by the bumetanide-inhibitable sodium-potassium-2 chloride cotransporter (NKCC2). Recycling of potassium back to the lumen through an apical potassium channel (ROMK) allows an adequate supply of potassium for optimal activity of the NKCC2. Chloride exits the basolateral side of the cell through a voltage-gated chloride channel (CIC-Kb), and sodium is expelled separately by the sodium-potassium adenosine triphosphatase cotransporter. Inactivating mutations in NKCC2, ROMK, and CIC-Kb have been identified in patients with Bartter syndrome [6–8].

Approximately 20% of filtered calcium is reabsorbed in the thick ascending limb, and inactivation of any of these three transport proteins can lead to hypercalciuria. Nephrocalcinosis occurs in almost all patients with mutations in NKCC2 or ROMK, but it is less common in patients with a mutation in the basolateral chloride channel CIC-Kb, even though patients with chloride-channel mutations currently make up the largest reported group [8]. This interesting observation is unexplained at present. In addition, a significant number of patients with Bartter syndrome have been found to have normal coding sequences for all three of these genes, indicating that mutations in other gene(s) may explain Bartter syndrome in some patients.

In contrast, the Gitelman variant of Bartter syndrome is associated with hypocalciuria. In this respect these patients resemble people treated with thiazide diuretics. In fact, mutations have been found in the thiazide-sensitive sodium chloride cotransporter of the distal tubule [9]. Hypomagnesemia is common and often severe, and patients with Gitelman syndrome do not develop nephrocalcinosis. ATP—adenosine triphosphate. (*From Simon and coworkers [8]; with permission.*)

**FIGURE 11-6**

Nephrocalcinosis. Ultrasound image of right kidney in a patient with primary hyperparathyroidism. Echogenicity of the renal cortex is comparable to that of the adjacent liver. The dense nephrocalcinosis is entirely medullary. (*Courtesy of Robert Botash, MD.*)

**FIGURE 11-7**

Noncontrast abdominal radiograph in a 24-year-old man with X-linked nephrolithiasis (Dent's disease). The patient had recurrent calcium nephrolithiasis beginning in childhood and developed end-stage renal disease requiring dialysis at 40 years of age. Extensive medullary calcinosis is evident.

X-LINKED NEPHROLITHIASIS (DENT'S DISEASE)

	Males who are affected	Females who are carriers
Low molecular weight proteinuria	Extreme	Absent, mild, or moderate
Other defects in proximal tubular function	Variable	Uncommon
Hypercalciuria	Occurs early in most	Present in half
Nephrocalcinosis	Nearly all have it	Rare
Calcium stones	Common but not universal	Uncommon
Renal failure	Common but not universal	Rare
Rickets	Present in some	Not reported

FIGURE 11-8

Syndromes of X-linked nephrolithiasis have been reported under various names, including Dent's disease in the United Kingdom, X-linked recessive hypophosphatemic rickets in Italy and France, and a syndrome of low molecular weight (LMW) proteinuria with hypercalciuria and nephrocalcinosis in Japanese schoolchildren. Mutations in a gene encoding a voltage-gated chloride channel (CIC-5) are present in all of these syndromes, establishing that they represent variants of one disease [10]. The disease occurs most often in boys, with microscopic hematuria, proteinuria, and hypercalciuria. Many but not all have recurrent nephrolithiasis from an early age. Affected males excrete extremely large quantities of LMW proteins, particularly β_2 -microglobulin and retinol-binding protein. Other defects of proximal tubular function, including hypophosphatemia, aminoaciduria, glycosuria, or hypokalemia, occur variably and often intermittently. Many affected males have mild to moderate polyuria and nocturia, and they often exhibit this symptom on presentation. Urinary acidification is usually normal, and patients do not have acidosis in the absence of advanced renal insufficiency. Nephrocalcinosis is common by the teenage years, and often earlier. Renal failure is common and often progresses to end-stage renal disease by the fourth or fifth decade, although some patients escape it. Renal biopsy documents a nonspecific pattern of interstitial fibrosis and tubular atrophy, with glomerular sclerosis that is probably secondary [11].

Rickets occurs early in childhood in some patients but is absent in most patients with X-linked nephrolithiasis (Dent's disease). In a few families, all affected males have had rickets. In other families, rickets is present in only one of several males sharing the same mutation. At present, the variability of this feature and other features of the disease is unexplained and may reflect dietary or environmental factors or the participation of other genes in the expression of the phenotype.

Females who are carriers often have mild to moderate LMW proteinuria. This abnormality can be used clinically as a screening test, but LMW protein excretion will not be abnormal in all heterozygous females. Approximately half of women who are carriers have hypercalciuria, but other biochemical abnormalities are rare. Although symptomatic nephrolithiasis and even renal insufficiency have been reported in female carriers, they are very uncommon.

The gene for CIC-5 that is mutated in X-linked nephrolithiasis (Dent's disease) is expressed in the endosomal vacuoles of the proximal tubule; it appears to be important in acidification of the endosome. Thus, defective endosomal function would explain the LMW proteinuria. The mechanism of hypercalciuria remains unexplained at present. This gene belongs to the family of voltage-gated chloride channels that includes CIC-Kb, one of the gene mutations in some patients with Bartter syndrome. To date, 32 mutations have been reported in 40 families, and nearly all are unique [11].

HYPEROXALURIA

Type	Mechanism	Clinical consequences
Primary (genetic): PH1	Functional deficiency of AGT	Nephrolithiasis Nephrocalcinosis and progressive renal failure Systemic oxalosis (kidneys, bones, cartilage, teeth, eyes, peripheral nerves, central nervous system, heart, vessels, bone marrow)
PH2	Functional deficiency of DGDH	Nephrolithiasis
Secondary: Dietary	Sources include for example spinach, rhubarb, beets, peanuts, chocolate, and tea	Increased risk of nephrolithiasis
Enteric	Enhanced oxalate absorption because of increased oxalate solubility, bile salt malabsorption, and altered gut flora (eg, inflammatory bowel disease and bowel resection)	Nephrolithiasis Nephrocalcinosis Systemic oxalosis (rarely)
Metabolism from excess of precursors	Ascorbate	Nephrolithiasis
	Ethylene glycol, glycine, glycerol, xylitol, methoxyflurane	Tubular obstruction by crystals leading to acute renal failure
Pyridoxine deficiency	Cofactor for AGT	Nephrolithiasis

FIGURE 11-9

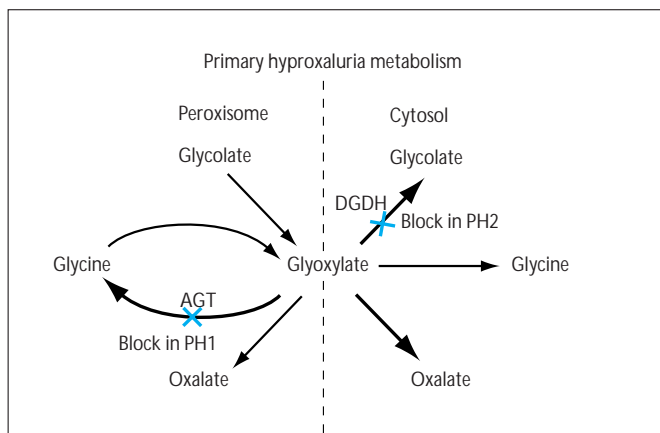
Oxalate is a metabolic end-product of limited solubility in physiologic solution. Thus, the organism is highly dependent on urinary excretion, which involves net secretion. Normal urine is supersaturated with respect to calcium oxalate. Crystallization is prevented by a number of endogenous inhibitors, including citrate. A mild excess of oxalate load, as occurs with excessive dietary intake, contributes to nephrolithiasis. A more severe oxalate overload, as in type 1 primary hyperoxaluria, can lead to organ damage through tissue deposition of calcium oxalate and possibly through the toxic effects of glyoxalate [12].

Two types of primary hyperoxaluria (PH) have been identified (Fig. 11-10), of which type 1 (PH1) is much more common. PH1 results from absolute or functional deficiency of the liver-specific enzyme alanine:glyoxalate aminotransferase (AGT). This deficiency leads to calcium oxalate nephrolithiasis in childhood, with nephrocalcinosis and progressive renal failure. Because the kidney is the main excretory route for oxalate, in the face of excessive oxalate production even mild degrees of renal insufficiency can lead to systemic deposition of oxalate in a wide variety of tissues. It is interesting that the liver itself is spared from calcium oxalate deposition. Clinical consequences include heart block and cardiomyopathy, severe peripheral vascular insufficiency and calcinosis cutis, and bone pain and fractures. Many of these conditions are exacerbated by the effects of end-stage renal disease. In contrast, PH2 is much more rare than is PH1. Patients with PH2 have recurrent nephrolithiasis. Nephrocalcinosis, renal failure, and systemic oxalosis have not been reported in PH2. The metabolic defect in PH2 appears to be a functional deficiency of D-glycerate dehydrogenase (DGDH) [12].

Secondary causes of hyperoxaluria include dietary excess, enteric hyperabsorption, and enhanced endogenous production resulting

from either exposure to metabolic precursors of oxalate or pyridoxine deficiency. Normally, dietary sources of oxalate account for only approximately 10% of urinary oxalate. Restriction of dietary oxalate can be effective in some patients with kidney stones who are hyperoxaluric, but even conscientious adherence to dietary restriction is disappointing in many patients who may have mild metabolic hyperoxaluria, an entity that probably exists but is poorly understood. Intestinal absorption of oxalate can be enhanced markedly in patients with bowel disease, particularly inflammatory bowel disease or after extensive bowel resection or jejunioleal bypass. In this setting, several mechanisms have been described including a) enhanced oxalate solubility as a consequence of binding of calcium to fatty acids in patients with fat malabsorption; b) a direct effect of malabsorbed bile salts to enhance absorption of oxalate by intestinal mucosa, and c) altered gut flora with reduction in the population of oxalate-metabolizing bacteria [4,12]. Because of the important role of the colon in absorbing oxalate, ileostomy abolishes enteric hyperoxaluria [4].

Excessive endogenous production of oxalate occurs in patients ingesting large quantities of ascorbic acid, which may increase the risk of nephrolithiasis. In the setting of acute exposure to large quantities of metabolic precursors, such as ingestion of ethylene glycol or administration of glycine or methoxyflurane, tubular obstruction by calcium oxalate crystals can lead to acute renal failure. Pyridoxine deficiency is associated with increased oxalate excretion clinically in humans and experimentally in animals; it can contribute to mild hyperoxaluria. In all patients with primary hyperoxaluria, a trial of pyridoxine therapy should be given, because some patients will have a beneficial response.

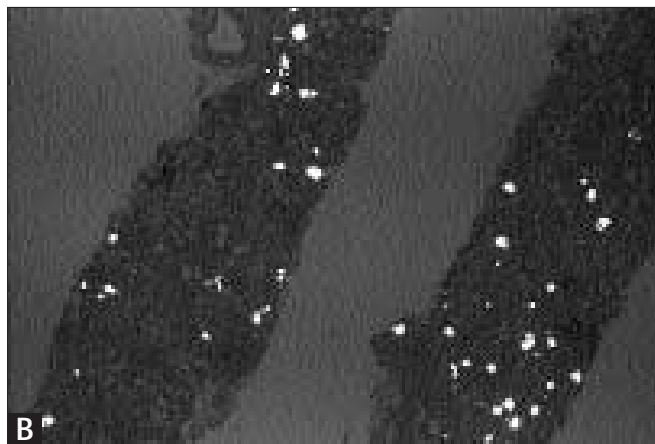
**FIGURE 11-10**

Metabolic events in the primary hyperoxalurias. Primary hyperoxaluria type 1 (PH1) results from functional deficiency of the peroxisomal enzyme alanine:glyoxylate aminotransferase (AGT). PH2 results from a deficiency of the cytosolic enzyme d-glycerate dehydrogenase (DGDH), which also functions as glyoxylate reductase. This figure presents a simplified illustration of the metabolic

consequences of these defects. Both diseases are inherited as autosomal recessive traits.

In PH1, much clinical, biochemical, and molecular heterogeneity exists. Liver AGT catalytic activity is absent in approximately two thirds of patients with PH1. It is detectable in the remaining third, however, in whom the enzyme is targeted to the mitochondria rather than peroxisomes. Absence of peroxisomal AGT activity leads to impaired transamination of glyoxylate to glycine, with excessive production of oxalate and, usually, glycolate. In PH2, deficiency of cytosolic DGDH results in overproduction of oxalate and glycine. Mild cases of PH1, without nephrocalcinosis or systemic oxalosis, resemble PH2 clinically, but the two usually can be distinguished by measurement of urinary glycolate and glycine. Assay of AGT activity in liver biopsy specimens can be diagnostic in PH1 even when renal failure prevents analysis of urinary excretion.

The gene encoding AGT has been localized to chromosome 2q37.3 and has been cloned and sequenced. Mutations in this gene have been identified in patients with absent enzymatic activity, abnormal enzyme targeting to mitochondria, aggregation of AGT within peroxisomes, and absence of both enzymatic activity and immunoreactivity. However, mutations have not been identified in all patients with PH1 who have been studied, and molecular diagnosis is not yet routinely available [12]. (*Adapted from Danpure and Purdue [12].*)

**FIGURE 11-11**

Sequential biopsies of a transplanted kidney documenting progressive recurrence of renal oxalosis. This patient with primary hyperoxaluria type I received renal transplantation, without liver transplantation, at 24 years of age. Panels A–D show tissue stained with hematoxylin

and eosin. Panels A–C show specimens viewed by polarization microscopy, all at the same low-power magnification, from biopsies taken after transplantation within the first year (A), third year (B),

(Continued on next page)

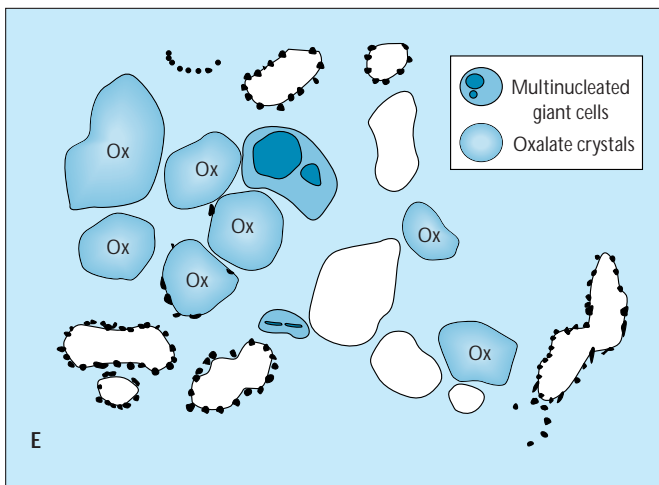
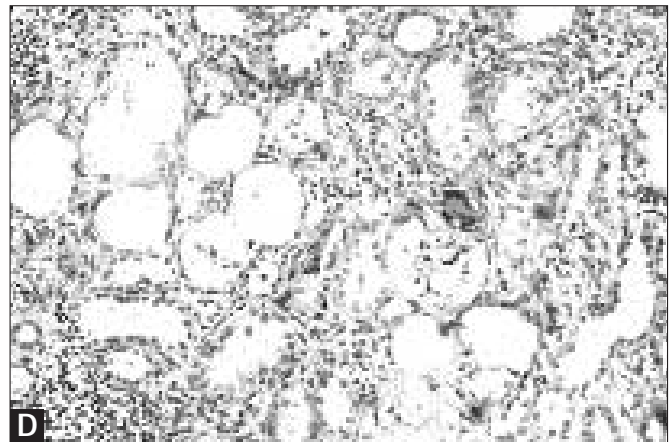
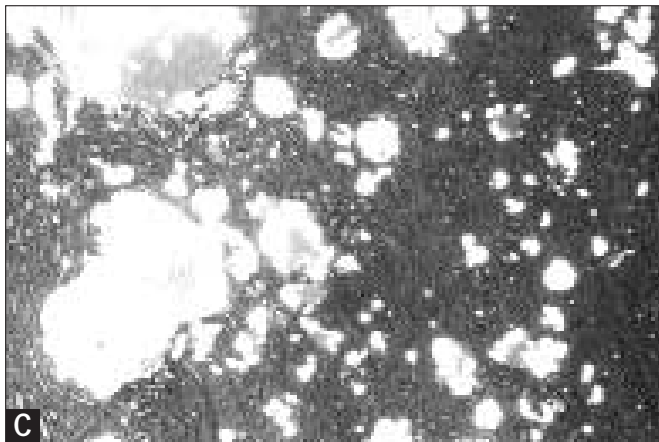


FIGURE 11-11 (Continued)

and fifth year (C), following renal transplantation. Deposition of oxalate crystals became progressively more severe with time, and the kidney failed after 5 years. Panel D illustrates a higher-power magnification, without polarization, of the biopsy at 5 years, showing a

radial array of oxalate crystals and phagocytosis of small crystals by multinucleated giant cells (E).

Conservative treatment of PH1 is of limited efficacy. Dietary restriction has little effect on the course of the disease. High-dose pyridoxine should be tried in all patients, but many patients do not respond. Strategies to prevent calcium oxalate stone formation include a high fluid intake (recommended in all patients), magnesium oxide (because magnesium increases the solubility of calcium oxalate salts), and inorganic phosphate. Lithotripsy or surgery may be necessary but do not alter the progression of nephrocalcinosis [12,13].

Hemodialysis is superior to peritoneal dialysis in its ability to remove oxalate, but neither one is able to maintain a rate of oxalate removal sufficient to keep up with the production rate in patients with PH1. Once end-stage renal disease develops, hemodialysis does not prevent the progression of systemic oxalosis. In some patients, renal transplantation accompanied by an aggressive program of management has been followed by a good outcome for years [14]. However, oxalosis often recurs in the transplanted kidney, particularly if any degree of renal insufficiency develops for any reason. In recent years, liver transplantation has been used with success, with or without renal transplantation, and offers the prospect of definitive cure. Results of liver transplantation are best in patients who have not yet developed significant renal insufficiency [12]. (Courtesy of Paul Shanley, MD.)

URIC ACID AND RENAL DISEASE

Disease	Clinical setting	Features	Therapeutic issues
Uric acid nephrolithiasis	Hyperuricosuria	Uric acid nephrolithiasis Calcium nephrolithiasis	Allopurinol; alkalinize urine Allopurinol
Acute uric acid nephropathy	Cytotoxic chemotherapy for leukemia or lymphoma; occasionally spontaneous	Intratubular obstruction by uric acid crystals in acidic urine	Prevention with allopurinol, fluids, and alkalinization Acute dialysis as indicated
Chronic gouty nephropathy	Gout or hyperuricemia in the setting of hypertension, preexisting renal disease, advanced age, vascular disease, inflammatory reaction, and chronic exposure to lead	Intrarenal tophi; sodium urate crystals in interstitium with accompanying destructive inflammatory reaction	Hemodialysis for renal failure
Familial hyperuricemic nephropathy	Autosomal dominant inheritance	Interstitial fibrosis, chronic inflammation; crystals are rare	No consensus regarding allopurinol

FIGURE 11-12

Uric acid contributes to the risk of kidney stones in several ways. Pure uric acid stones occur in patients with hyperuricosuria, particularly when the urine is acidic. Thus, therapy involves both allopurinol and alkalinization with potassium alkali salts. Hyperuricosuria also promotes calcium oxalate stone formation. In these patients, calcium nephrolithiasis can be prevented by therapy with allopurinol. The mechanism may involve heterogeneous nucleation of calcium oxalate by uric acid microcrystals, binding of endogenous inhibitors of calcium crystallization, or “salting out” of calcium oxalate by urate [4].

Acute uric acid nephropathy occurs most often in the setting of brisk cell lysis from cytotoxic therapy or radiation for myeloproliferative or lymphoproliferative disorders or other tumors highly responsive to therapy. Uric acid nephropathy can uncommonly occur spontaneously in malignancies or other states of high uric acid production. Examples are infants with the Lesch-Nyhan syndrome who have excessive uric acid production resulting from deficiency of hypoxanthine-guanine phosphoribosyltransferase deficiency and, rarely, adults with gout who become volume-contracted and whose urine is concentrated and acidic. The mechanism involves intratubular obstruction by crystals of uric acid in the setting of an acute overwhelming load of uric acid, particularly in acidic urine. In recent years, the widespread use of an effective prophylactic regimen for chemotherapy has made acute uric acid nephropathy much less common [15]. This regimen includes preparation of the patient with high-dose allopurinol, volume-expanding the patient to maintain a dilute urine, and alkaline diuresis. In patients whose tumor lysis leads to hyperphosphatemia, however, it is important to discontinue urinary alkalinization or else calcium phosphate precipitation may occur. Occasionally, patients will develop renal failure despite these measures. In such patients, hemodialysis is preferable to peritoneal

dialysis because of the higher clearance rates for uric acid. Frequent hemodialysis, even multiple times per day, may be necessary to prevent extreme hyperuricemia and facilitate recovery of renal function. A modification of continuous arteriovenous hemodialysis has recently been reported to be effective in management of these patients [16].

Chronic gouty nephropathy is a term referring to deposition of sodium urate crystals in the renal interstitium, with an accompanying destructive inflammatory reaction. As a specific entity with intrarenal tophi, gouty nephropathy appears to have become uncommon. It appears clear that long-standing hyperuricemia alone is not sufficient to cause this condition in most patients, and that renal failure in patients with hyperuricemia or gout is almost always accompanied by other predisposing conditions, particularly hypertension or exposure to lead [17].

Familial hyperuricemic nephropathy is an entity that now has been reported in over 40 kindreds. It is characterized by recurrent gout, often occurring in youth and even childhood; hyperuricemia; and renal failure. Histopathology reveals interstitial inflammation and fibrosis, almost always without evidence of urate crystal deposition, although this has been found in two patients. In contrast to gouty nephropathy, hypertension usually is absent until renal failure is advanced. The hyperuricemia appears to reflect decreased renal excretion of urate rather than overproduction of urate. Although hyperuricemia precedes and is disproportionate to any degree of renal failure, the role, if any, that uric acid plays in the pathogenesis of the renal failure remains unclear. There is no consensus among authors regarding the potential value of allopurinol in this disease. The inheritance follows an autosomal dominant pattern, but, beyond this, the genetics of the disease are not understood [18,19].

References

1. Hebert SC: Extracellular calcium-sensing receptor: implications for calcium and magnesium handling in the kidney. *Kidney Int* 1996, 50:2129–2139.
2. Riccardi D, Hall A, Xu J, *et al.*: Localization of the extracellular Ca²⁺ (polyvalent) cation-sensing receptor in kidney. *Am J Physiol (Renal Fluid Electrolyte Physiol)*, 1998, in press.
3. Wrong OM: Nephrocalcinosis. In *The Oxford Textbook of Clinical Nephrology*. Edited by Davison AM, *et al.* London: Oxford University Press; 1997:1378–1396.
4. Coe FL, Parks JH, Asplin JR: The pathogenesis and treatment of kidney stones. *N Engl J Med* 1992, 327:1141–1152.
5. Buckalew VM: Nephrolithiasis in renal tubular acidosis. *J Urol* 1989, 141:731–737.
6. Simon DB, Karet FE, Hamdan JM, *et al.*: Bartter's syndrome, hypokalaemic alkalosis with hypercalciuria, is caused by mutations in the Na-K-2Cl cotransporter NKCC2. *Nature Genet* 1996, 13:183–188.
7. Simon DB, Karet FE, Rodriguez-Soriano J, *et al.*: Genetic heterogeneity of Bartter's syndrome revealed by mutations in the K⁺ channel, ROMK. *Nature Genet* 1996, 14:152–156.
8. Simon DB, Bindra RS, Mansfield TA, *et al.*: Mutations in the chloride channel gene, CLCNKB, cause Bartter's syndrome type III. *Nature Genet* 1997, 17:171–178.
9. Simon DB, Nelson-Williams C, Bia MJ, *et al.*: Gitelman's variant of Bartter's syndrome, inherited hypokalaemic alkalosis, is caused by mutations in the thiazide-sensitive Na-Cl cotransporter. *Nature Genet* 1996, 12:24–30.
10. Lloyd SE, Pearce SHS, Fisher SE, *et al.*: A common molecular basis for three inherited kidney stone diseases. *Nature* 1996, 379:445–449.
11. Scheinman SJ: X-linked hypercalciuric nephrolithiasis: clinical syndromes and chloride channel mutations. *Kidney Int* 1998, 53:3–17.
12. Danpure CJ, Purdue PE: Primary hyperoxaluria. In *The Metabolic and Molecular Bases of Inherited Disease*, edn 6. Edited by Scriver CR, *et al.* New York: McGraw-Hill; 1995:2385–2424.
13. Scheinman JI: Primary hyperoxaluria. *Miner Electrolyte Metab* 1994, 20:340–351.
14. Katz A, Freese D, Danpure CJ, *et al.*: Success of kidney transplantation in oxalosis is unrelated to residual hepatic enzyme activity. *Kidney Int* 1992, 42:1408–1411.
15. Razi E, Arlin ZA, Ahmed T, *et al.*: Incidence and treatment of tumor lysis syndrome in patients with acute leukemia. *Acta Haematol* 1994, 91:171–174.
16. Pichette V, Leblanc M, Bonnardeaux A, *et al.*: High dialysate flow rate continuous arteriovenous hemodialysis: a new approach for the treatment of acute renal failure and tumor lysis syndrome. *Am J Kidney Dis* 1994, 23:591–596.
17. Beck LH: Requiem for gouty nephropathy. *Kidney Int* 1986, 30:280–287.
18. Puig JG, Miranda ME, Mateos FA, *et al.* Hereditary nephropathy associated with hyperuricemia and gout. *Arch Intern Med* 1993, 153:357–365.
19. Reiter L, Brown MA, Edmonds J: Familial hyperuricemic nephropathy. *Am J Kidney Dis* 1995, 25:235–241.