

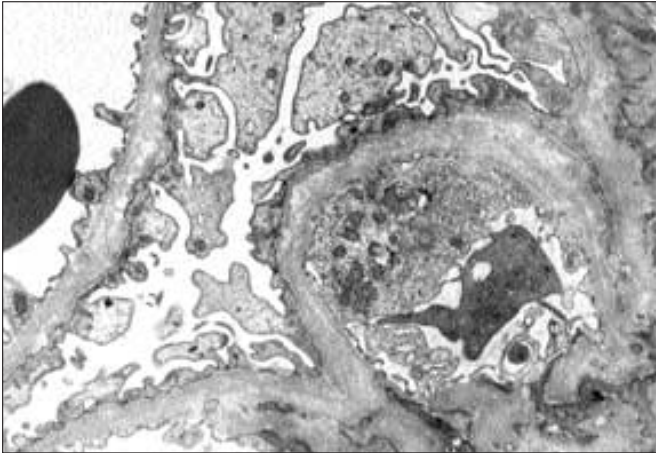
Heredofamilial and Congenital Glomerular Disorders

Arthur H. Cohen
Richard J. Glassock

The principal characteristics of some of the more common hereditary and congenital glomerular disorders are described and illustrated. Diabetes mellitus, the most common hereditary glomerular disease, is illustrated in Volume IV, Chapter 1. These disorders are inherited in a variety of patterns (X-linked, autosomal dominant, or autosomal recessive). Many of these disorders appear to be caused by defective synthesis or assembly of critical glycoprotein (collagen) components of the glomerular basement membrane.

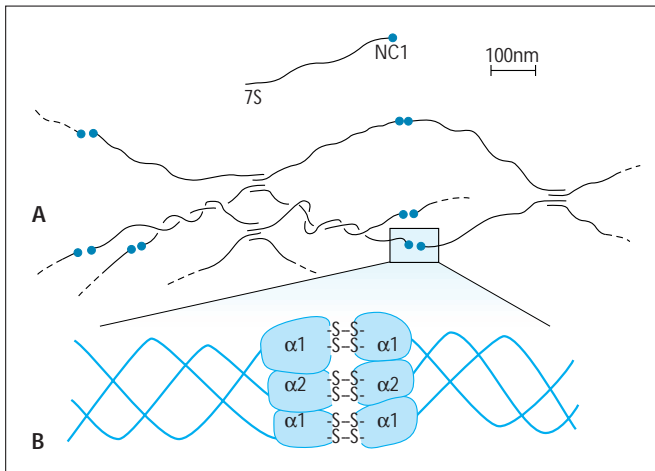
CHAPTER

3

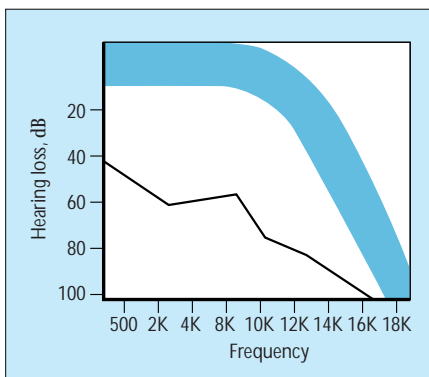
**FIGURE 3-1**

Alport's syndrome. Alport's syndrome (hereditary nephritis) is a hereditary disorder in which glomerular and other basement membrane collagen is abnormal. This disorder is characterized clinically by hematuria with progressive renal insufficiency and proteinuria. Many patients have neurosensory hearing loss and abnormalities of

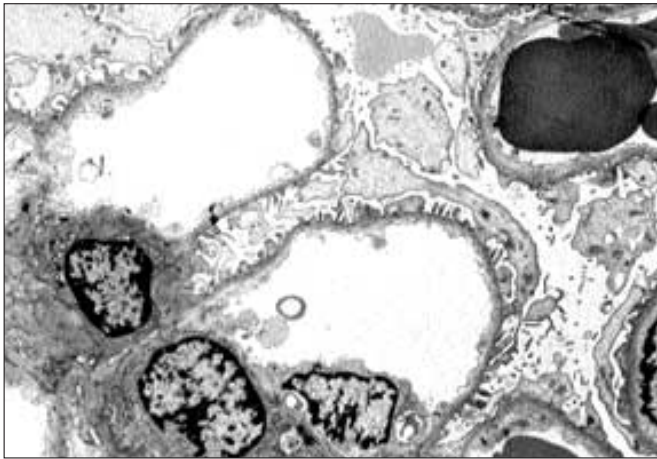
the eyes. The disease is inherited as an X-linked trait; in some families, however, autosomal recessive and perhaps autosomal dominant forms exist. Clinically, the disease is more severe in males than in females. End-stage renal disease develops in persons 20 to 40 years of age. In some families, ocular manifestations, thrombocytopenia with giant platelets, esophageal leiomyomata, or all of these also occur. In the X-linked form of Alport's syndrome, mutations occur in genes encoding the α -5 chain of type IV collagen (COL4A5). In the autosomal recessive form of this syndrome, mutations of either α -3 or α -4 chain genes have been described. On light microscopy, in the early stages of the disease the glomeruli appear normal. With progression of the disease, however, an increase in the mesangial matrix and segmental sclerosis develop. Interstitial foam cells are common but are not used to make a diagnosis. Results of immunofluorescence typically are negative, except in glomeruli with segmental sclerosis in which segmental immunoglobulin M and complement (C3) are in the sclerotic lesions. Ultrastructural findings are diagnostic and consist of profound abnormalities of glomerular basement membranes. These abnormalities range from extremely thin and attenuated to considerably thickened membranes. The thickened glomerular basement membranes have multiple layers of alternating medium and pale staining strata of basement membrane material, often with incorporated dense granules. The subepithelial contour of the basement membrane typically is scalloped.

**FIGURE 3-2**

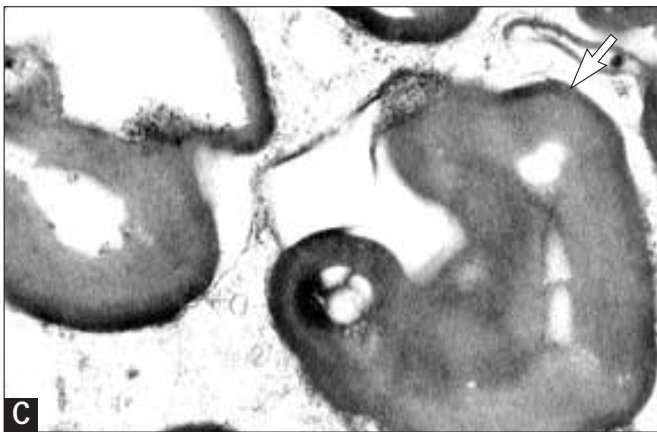
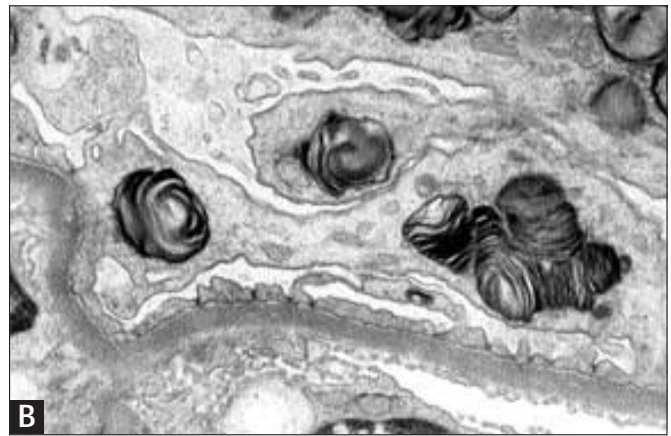
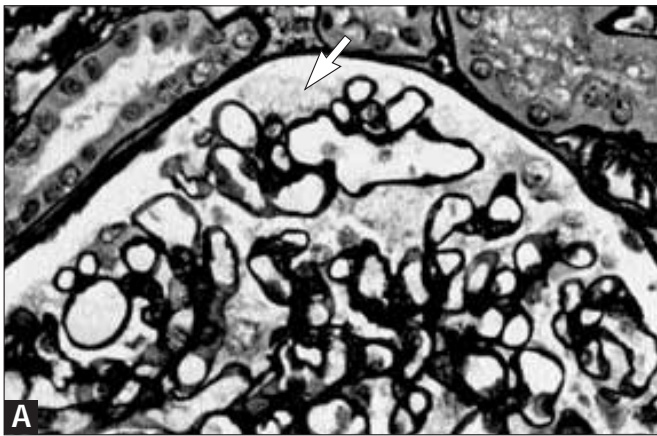
Schematic of basement membrane collagen type IV. The postulated arrangement of type IV collagen chains in a normal glomerular basement membrane is illustrated. The joining of noncollagen (NC-1) and 7S domains creates a lattice (chicken wire) arrangement (A). In the glomerular basement membrane, α 1 and α 2 chains predominate in the triple helix (B), but α 3, 4, 5, and 6 chains are also found (not shown). Disruption of synthesis of any of these chains may lead to anatomic and pathologic alternations, such as those seen in Alport's syndrome. Arrows indicate fibrils. (From Abrahamson and coworkers [1]; with permission.)

**FIGURE 3-3**

Neurosensory hearing defect in Alport's syndrome. In patients with adult onset Alport's syndrome, classic X-linked sensorineural hearing defects occur. These defects often begin with an auditory loss of high-frequency tone, as shown in this audiogram. The shaded area represents normal ranges. (Modified from Gregory and Atkin [2]; with permission.)

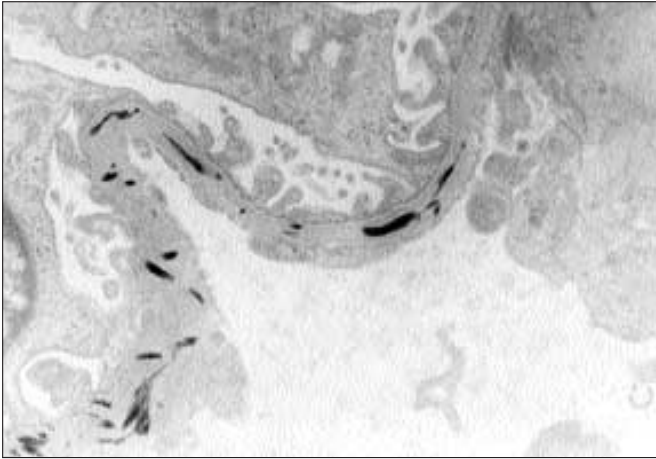
**FIGURE 3-4**

Thin basement membrane nephropathy. Glomeruli with abnormally thin basement membranes may be a manifestation of benign familial hematuria. Glomeruli with thin basement membranes may also occur in persons who do not have a family history of renal disease but who have hematuria, low-grade proteinuria, or both. Although the ultrastructural abnormalities have some similarities in common with the capillary basement membranes of Alport's syndrome, these two glomerulopathies are not directly related. Clinically, persistent microscopic hematuria or occasional episodic gross hematuria are important features. Nonrenal abnormalities are absent. On light microscopy, the glomeruli are normal; no deposits are seen on immunofluorescence. Here, the electron microscopic abnormalities are diagnostic; all or virtually all glomerular basement membranes are markedly thin (<200 nm in adults) without other features such as splitting, layering, or abnormal subepithelial contours.

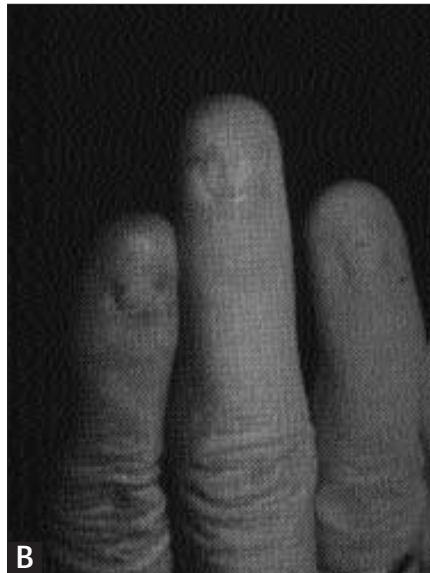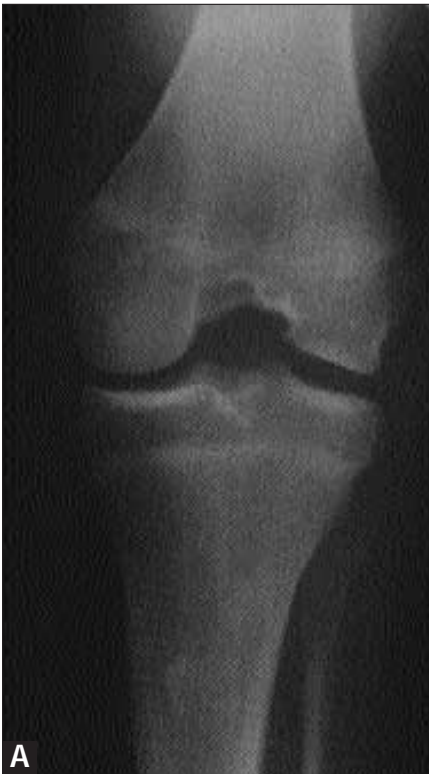**FIGURE 3-5** (see Color Plate)

Fabry's disease. Fabry's disease, also known as *angiokeratoma corporis diffusum* or Anderson-Fabry's disease, is the result of deficiency

of the enzyme α -galactosidase with accumulation of sphingolipids in many cells. In the kidney, accumulation of sphingolipids especially affects glomerular visceral epithelial cells. Deposition of sphingolipids in the vascular tree may lead to premature coronary artery occlusion (angina or myocardial infarction) or cerebrovascular insufficiency (stroke). Involvement of nerves leads to painful acroparesthesias and decreased perspiration (anhidrosis). The most common renal manifestation is that of proteinuria with progressive renal insufficiency. On light microscopy, the morphologic abnormalities of the glomeruli primarily consist of enlargement of visceral epithelial cells and accumulation of multiple uniform small vacuoles in the cytoplasm (arrow in Panel A). Ultrastructurally, the inclusions are those of whorled concentric layers appearing as "zebra bodies" or myeloid bodies representing sphingolipids (B). These structures also may be observed in mesangial and endothelial cells and in arterial and arteriolar smooth muscle cells and tubular epithelia. At considerably higher magnification, the inclusions are observed to consist of multiple concentric alternating clear and dark layers, with a periodicity ranging from 3.9 to 9.8 nm. This fine structural appearance (best appreciated at the arrow) is characteristic of stored glycolipids (C).

**FIGURE 3-6**

Electron microscopy of nail-patella syndrome. This disorder having skeletal and renal manifestations affects the glomeruli, with accumulation of banded collagen fibrils within the substance of the capillary basement membrane. This accumulation appears as empty lacunae when the usual stains with electron microscopy (lead citrate and uranyl acetate) are used. However, as here, the fibrils easily can be identified with the use of phosphotungstic acid stain in conjunction with or instead of typical stains. Note that this disorder differs structurally from collagen type III glomerulopathy in which the collagen fibrils are subendothelial and not intramembranous in location. Patients with nail-patella syndrome may develop proteinuria, sometimes in the nephrotic range, with variable progression to end-stage renal failure. No distinguishing abnormalities are seen on light microscopy.

**FIGURE 3-7**

Radiography of nail-patella syndrome. The skeletal manifestations of nail-patella syndrome are characteristic and consist of absent patella and absent and dystrophic nails. These photographs illustrate absent patella (A) and the characteristic nail changes (B) that occur in patients with the disorder. (From Gregory and Atkin [2]; with permission.)

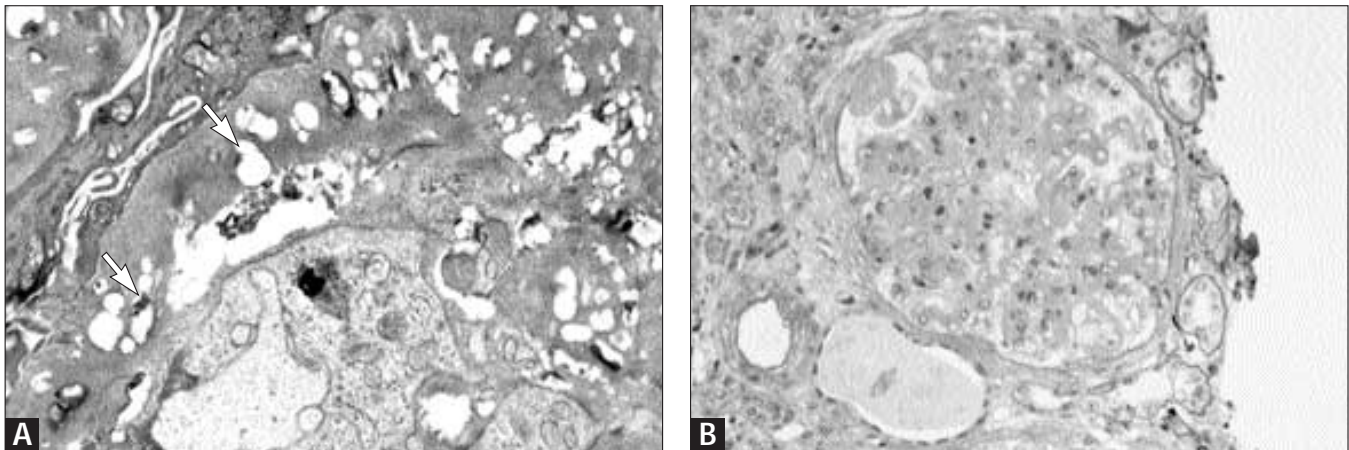


FIGURE 3-8 (see Color Plate)

Lecithin-cholesterol acyl transferase deficiency. Lipid accumulation occurs in this hereditary metabolic disorder, especially in extracellular sites throughout glomerular basement membranes and the mesangial matrix. **A**, On electron microscopy the lipid appears as multiple small lacunae, often with small round dense granular or membranous structures (arrows). Lipid-containing monocytes may be in the capillary lumina. **B**, The mesangial regions are widened on light microscopy, usually with expansion of the matrix that stains less intensely than normal. Basement

membranes are irregularly thickened. Some capillary lumina may contain foam cells. Although quite rare, this autosomal recessive disease has been described in most parts of the world; however, it occurs most commonly in Norway. Patients exhibit proteinuria, often with microscopic hematuria usually noted in childhood. Renal insufficiency may develop in the fourth or fifth decade of life and may progress rapidly. Nonrenal manifestations include corneal opacification, hemolytic anemia, early atherosclerosis, and sea-blue histiocytes in the bone marrow and spleen.

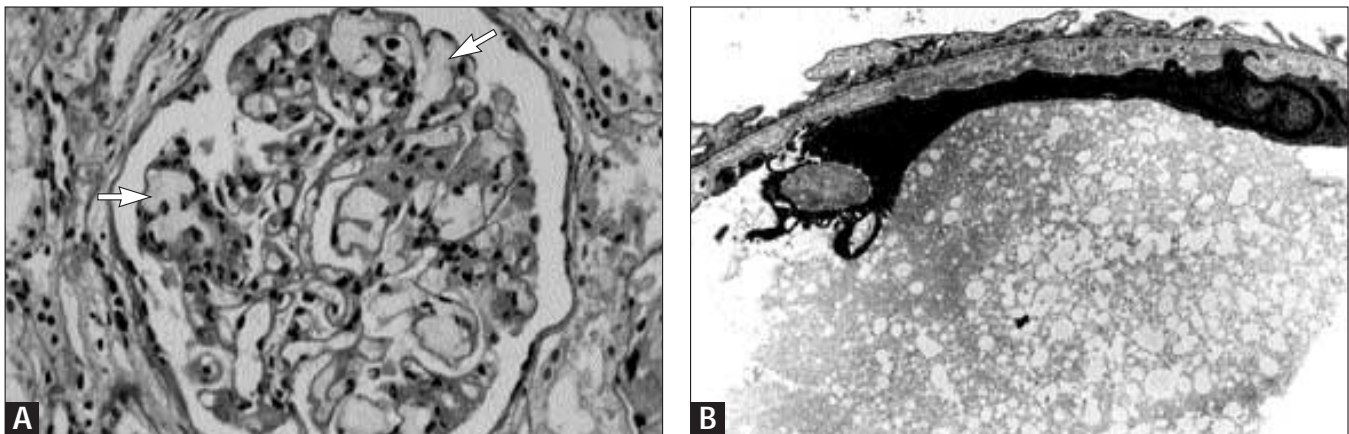


FIGURE 3-9 (see Color Plate)

Lipoprotein glomerulopathy. Patients with this rare disease, which often is sporadic (although some cases occur in the same family), exhibit massive proteinuria. Lipid profiles are characterized by increased plasma levels of cholesterol, triglycerides, and very low density lipoproteins. Most patients have heterozygosity for apolipoprotein E2/3 or E2/4. **A**, The glomeruli are the sites of massive intracapillary accumulation of lipoproteins, which appear as slightly tan masses (thrombi) dilating capillaries (arrows). Segmental

mesangial hypercellularity or mesangiolysis may be present. With immunostaining for β -lipoprotein, apolipoproteins E and B are identified in the luminal masses. **B**, Electron microscopic findings indicate the thrombi consist of finely granular material with numerous vacuoles (lipoprotein). Lipoprotein glomerulopathy may progress to renal insufficiency over a long period of time. Recurrence of the lesions in a transplanted organ has been reported infrequently. Lipid-lowering agents are mostly ineffective.

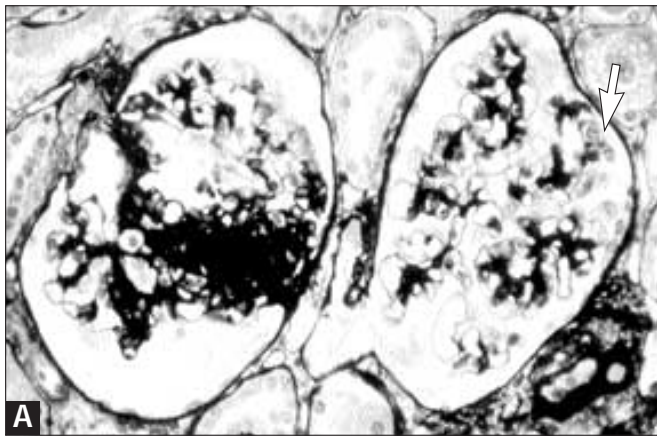
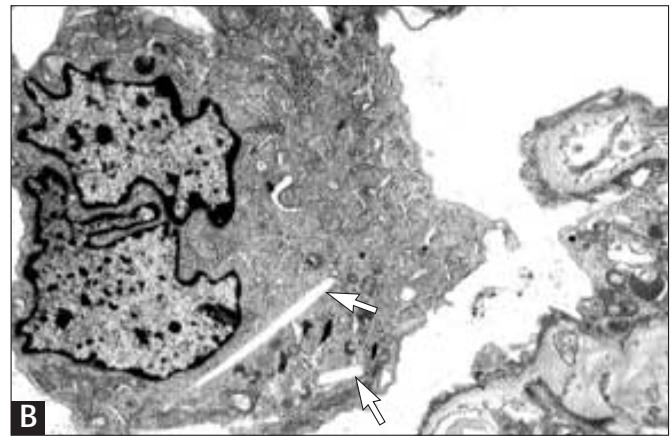


FIGURE 3-10 (see Color Plate)

Nephropathic cystinosis. In older children and young adults, compared with young children, patients with cystinosis commonly exhibit glomerular involvement rather than tubulointerstitial disease. Proteinuria and renal insufficiency are the typical initial manifestations. **A**, As the most constant abnormality on light microscopy, glomeruli



have occasionally enlarged and multinucleated visceral epithelial cells (arrow). As the disease progresses, segmental sclerosis becomes evident as in the photomicrograph. **B**, Crystalline inclusions are identified on electron microscopy. The crystals of cysteine are usually dissolved in processing, leaving an empty space as shown here by the arrows.

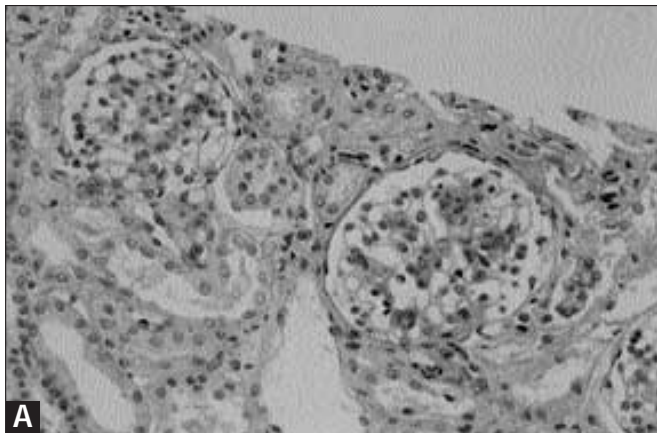
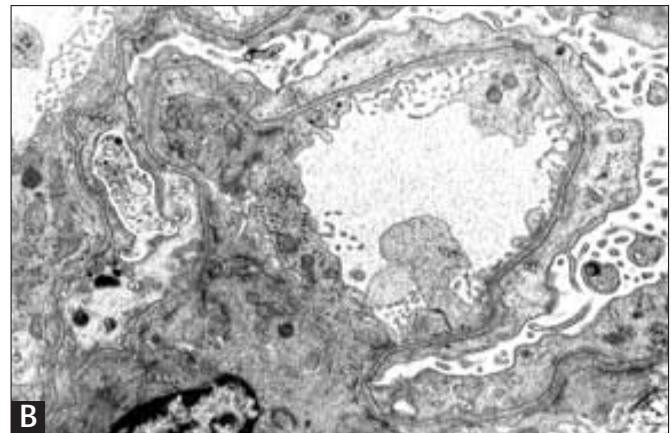
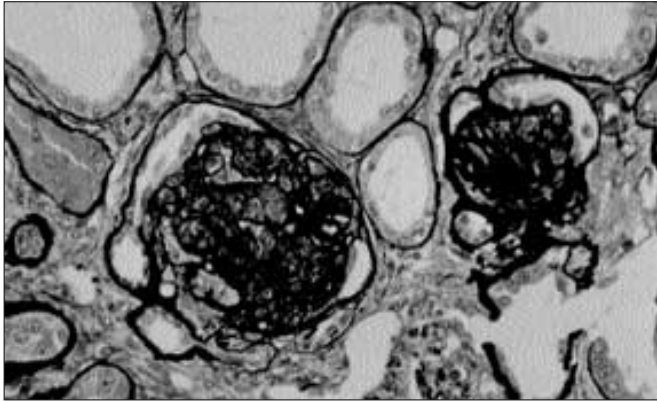


FIGURE 3-11 (see Color Plate)

Finnish type of congenital nephrotic syndrome. Several disorders are responsible for nephrotic syndrome within the first few months to first year of life. The most common and important of these is known as congenital nephrotic syndrome of Finnish type because the initial descriptions emphasized the more common occurrence in Finnish families. This nephrotic syndrome is an inherited disorder in which infants exhibit massive proteinuria shortly after birth; typically, the placenta is enlarged. This disorder can be diagnosed *in utero*; increased α -fetoprotein levels in amniotic fluid is a common feature. **A**, The microscopic appearance of



the kidneys is varied. Some glomeruli are small and infantile without other alterations, whereas others are enlarged, more mature, and have diffuse mesangial hypercellularity. Because of the massive proteinuria, some tubules are microcystically dilated, a finding responsible for the older term for this disorder, *microcystic disease*. Because this syndrome is primarily a glomerulopathy, the tubular abnormalities are a secondary process and should not be used to designate the name of the disease. **B**, On electron microscopy, complete effacement of the foot processes of visceral epithelial cells is observed.

**FIGURE 3-12**

Diffuse mesangial sclerosis. This disorder is exhibited within the first few months of life with massive proteinuria, often with

hematuria and progressive renal insufficiency. Currently, no evidence exists that this disorder is an inherited process with genetic linkage. The glomeruli characteristically are small compact masses of extracellular matrix with numerous or all capillary lumina being obliterated. As here, the visceral epithelial cells typically are arranged as a corona or crown overlying the contracted capillary tufts. Earlier stages of glomerular involvement are characterized by variable increase in mesangial cellularity. Immunofluorescence is typically negative for immunoglobulin deposits because this disorder is not immune mediated. In some patients, diffuse mesangial sclerosis may be part of the triad of the Drash syndrome characterized by ambiguous genitalia, Wilms' tumor, and diffuse mesangial sclerosis. In some patients, only two of the three components may be present; however, some investigators consider all patients with diffuse mesangial sclerosis to be at risk for the development of Wilms' tumor even in the absence of genital abnormalities. Thus, close observation or bilateral nephrectomy as prophylaxis against the development of Wilms' tumor is employed occasionally.

References

1. Abrahamson D, Van der Heuvel GB, Clapp WL, *et al.*: Nephritogenic antigens in the glomerular basement membrane. In *Immunologic Renal Diseases*. Edited by Nielson EG, Couser, WG. Philadelphia: Lippincott-Raven, 1997.
2. Gregory M, Atkin C: Alport's syndrome, Fabry disease and nail-patella syndrome. In *Diseases of the Kidney*, Vol. I. edn 6. Edited by Schrier RW, Gottschalk CW. Boston: Little Brown, 1995.