

Acute Renal Failure in the Transplanted Kidney

Kim Solez
Lorraine C. Racusen

Acute renal failure (ARF) in the transplanted kidney represents a high-stakes area of nephrology and of transplantation practice. A correct diagnosis can lead to rapid return of renal function; an incorrect diagnosis can lead to loss of the graft and severe sequelae for the patient. The diagnostic possibilities are many (Fig. 10-1) and treatments quite different, although the clinical presentations of new-onset functional renal impairment and of persistent nonfunctioning after transplant may be identical.

In transplant-related ARF percutaneous kidney allograft biopsy is crucial in differentiating such diverse entities as acute rejection (Figs. 10-2 to 10-9), acute tubular necrosis (Figs. 10-10 to 10-14), cyclosporine toxicity (Figs. 10-15 and 10-16), posttransplant lymphoproliferative disorder (Fig. 10-17), and other, rarer, conditions.

In the case of acute rejection, standardization of transplant biopsy interpretation and reporting is necessary to guide therapy and to establish an objective endpoint for clinical trials of new immunosuppressive agents. The Banff Classification of Renal Allograft Pathology [1] is an internationally accepted standard for the assessment of renal allograft biopsies sponsored by the International Society of Nephrology Commission of Acute Renal Failure. The classification had its origins in a meeting held in Banff, Alberta, in the Canadian Rockies, in August, 1991, where subsequent meetings have been held every 2 years. Hot topics likely to influence the Banff Classification of Renal Allograft Pathology in 1999 and beyond are shown in Figs. 10-17 to 10-19.

CHAPTER

10

Acute Rejection

DIAGNOSTIC POSSIBILITIES IN TRANSPLANT-RELATED ACUTE RENAL FAILURE

1. Acute (cell-mediated) rejection
2. Delayed-appearing antibody-mediated rejection
3. Acute tubular necrosis
4. Cyclosporine or FK506 toxicity
5. Urine leak
6. Obstruction
7. Viral infection
8. Post-transplant lymphoproliferative disorder
9. Vascular thrombosis
10. Prerenal azotemia

FIGURE 10-1

Diagnostic possibilities in transplant-related acute renal failure.

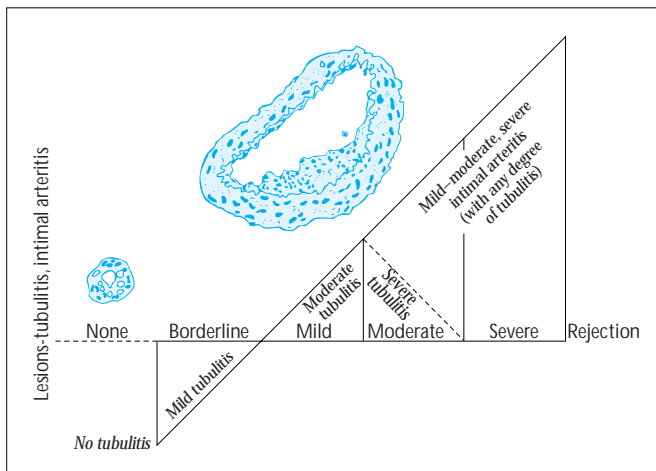


FIGURE 10-2

Diagnosis of rejection in the Banff classification makes use of two basic lesions, tubulitis and intimal arteritis. The 1993–1995 Banff classification depicted in this figure is the standard in use in virtually all current clinical trials and in many individual transplant units. In this construct, rejection is regarded as a continuum of mild, moderate, and severe forms. The 1997 Banff classification is similar, having the same threshold for rejection diagnosis, but it recognizes three different histologic types of acute rejection: tubulointerstitial, vascular, and transmural. The quotation marks emphasize the possible overlap of features of the various types (eg, the finding of tubulitis should not dissuade the pathologist from conducting a thorough search for intimal arteritis).

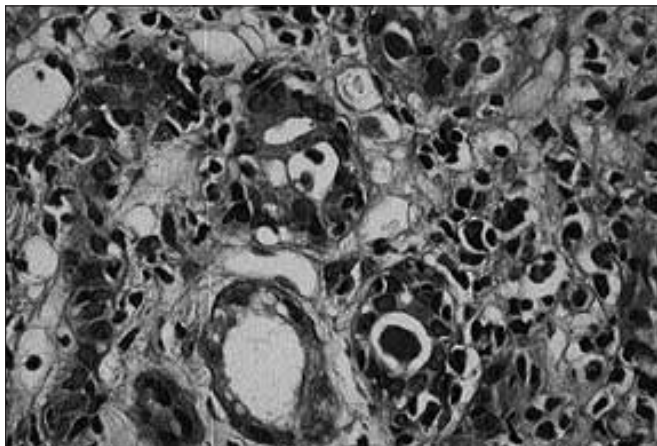


FIGURE 10-3

Tubulitis is not absolutely specific for acute rejection. It can be found in mild forms in acute tubular necrosis, normally functioning kidneys, and in cyclosporine toxicity and in conditions not related to rejection. Therefore, quantitation is necessary. The number of lymphocytes situated between and beneath tubular epithelial cells is compared with the number of tubular cells to determine the severity of tubulitis. Four lymphocytes per most inflamed tubule cross section or per ten tubular cells is required to reach the threshold for diagnosing rejection. In this figure, the two tubule cross sections in the center have eight mononuclear cells each. Rejection with intimal arteritis or transmural arteritis can occur without any tubulitis whatsoever, although usually in well-established rejection both tubulitis and intimal arteritis are observed.

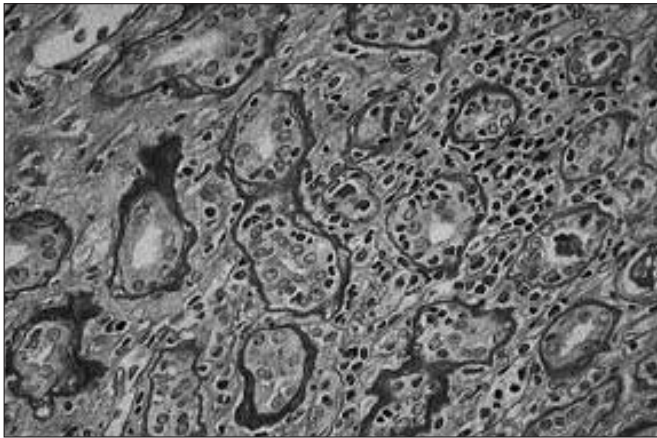


FIGURE 10-4 (see Color Plate)

In this figure the tubules with lymphocytic invasion are atrophic with thickened tubular basement membranes. There are 13 or 14 lymphocytes per tubular cross section. This is an example of how a properly performed periodic acid-Schiff (PAS) stain should look. The Banff classification is critically dependent on proper performance of PAS staining. The invading lymphocytes are readily apparent and countable in the tubules. In the Banff 1997 classification one avoids counting lymphocytes in atrophic tubules, as tubulitis there is more “nonspecific” than in nonatrophied tubules. (From Solez *et al.* [1]; with permission.)

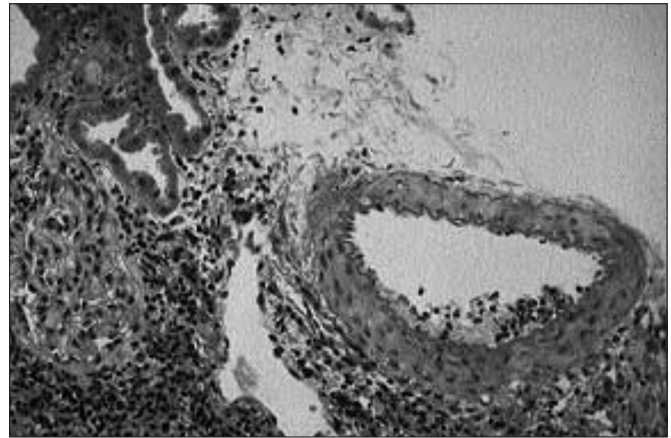


FIGURE 10-5

Intimal arteritis in a case of acute rejection. Note that more than 20 lymphocytes are present in the thickened intima. With this lesion, however, even a single lymphocyte in this site is sufficient to make the diagnosis. Thus, the pathologist must search for subtle intimal arteritis lesions, which are highly reliable and specific for rejection. (From Solez *et al.* [1]; with permission.)

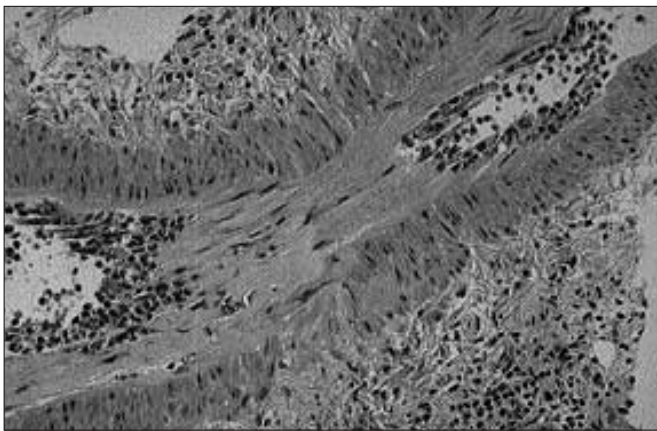


FIGURE 10-6

Artery in longitudinal section shows a more florid intimal arteritis than that in Figure 10-5. Aggregation of lymphocytes is also seen in the lumen, but this is a nonspecific change. The reporting for some clinical trials has involved counting lymphocytes in the most inflamed artery, but this has not been shown to correlate with clinical severity or outcome, whereas the presence or absence of the lesion has been shown to have such a correlation. (From Solez *et al.* [1]; with permission.)

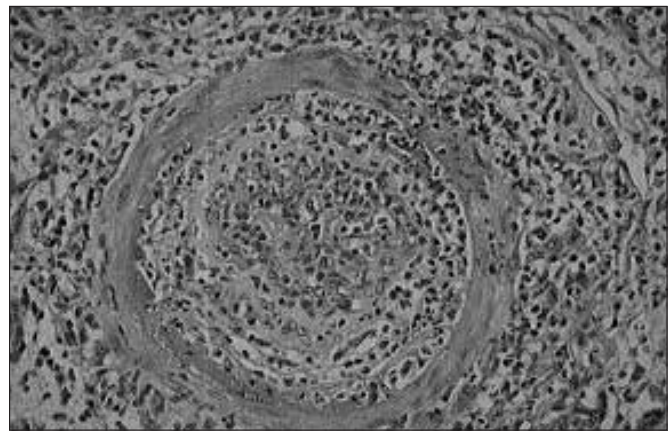


FIGURE 10-7

Transmural arteritis with fibrinoid change. In addition to the influx of inflammatory cells there has been proliferation of modified smooth muscle cells migrated from the media to the greatly thickened intima. Note the fibrinoid change at lower left and the penetration of the media by inflammatory cells at the upper right. Patients with these types of lesions have a less favorable prognosis, greater graft loss, and poorer long-term function as compared with patients with intimal arteritis alone. These sorts of lesions are also common in antibody-mediated rejection (see Fig. 10-9).

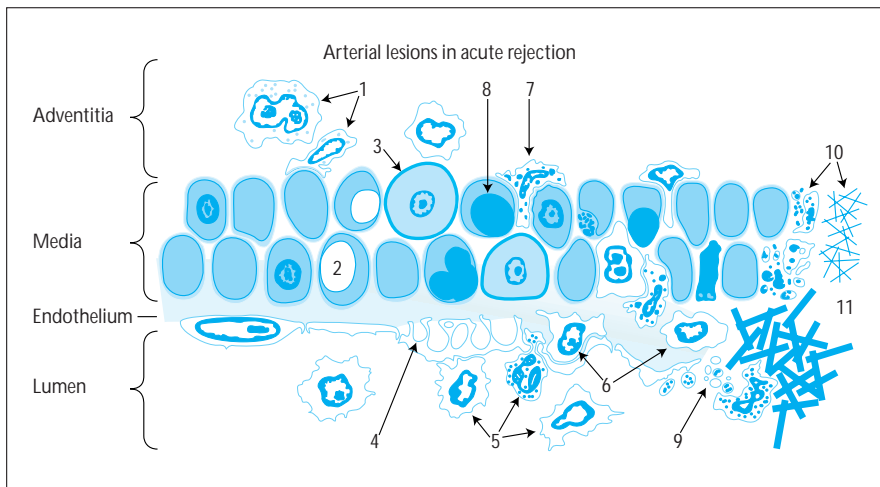
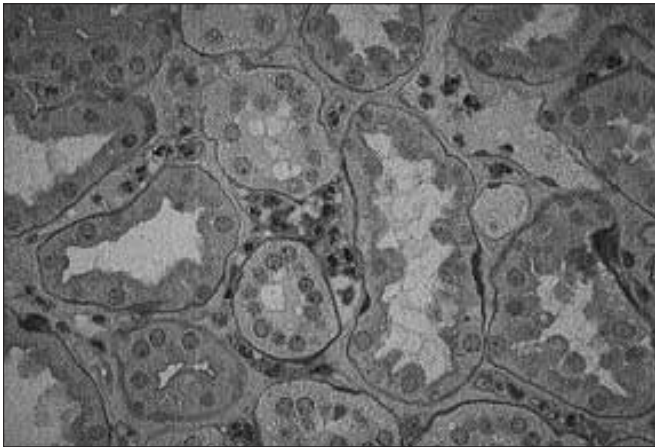
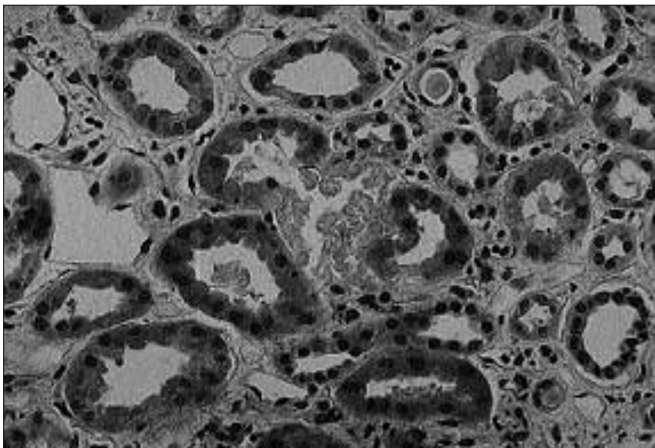
**FIGURE 10-8**

Diagram of arterial lesions of acute rejection. The initial changes (1–5) before intimal arteritis (6) occurs are completely nonspecific. These early changes are probably mechanically related to the diagnostic lesions but can occur as a completely self-limiting phenomenon unrelated to clinical rejection. Lesions 7 to 10 are those characteristic of “transmural” rejection. Lesion 1 is perivascular inflammation; lesion 2, myocyte vacuolization; lesion 3, apoptosis; lesion 4, endothelial activation and prominence; lesion 5, leukocyte adherence to the endothelium; lesion 6 (specific), penetration of inflammatory cells under the endothelium (intimal arteritis); lesion 7, inflammatory cell penetration of the media; lesion 8, necrosis of medial smooth muscle cells; lesion 9, platelet aggregation; lesion 10, fibrinoid change; and lesion 11 is thrombosis.

**FIGURE 10-9** (see Color Plate)

Antibody-mediated rejection with aggregates of polymorphonuclear leukocytes (polymorphs) in peritubular capillaries. This lesion is a feature of both classic hyperacute rejection and of later appearing antibody-mediated rejection, which is by far the more common entity. Antibody- and cell-mediated rejection can coexist, so one may find both tubulitis and intimal arteritis along with this lesion; however many cases of antibody-mediated rejection have a paucity of tubulitis [2]. The polymorph aggregates can be subtle, another reason for looking with care at the biopsy that appears to show “nothing.”

Acute Tubular Necrosis

**FIGURE 10-10** (see Color Plate)

Acute tubular necrosis in the allograft. Unlike “acute tubule necrosis” in native kidney, in this condition actual necrosis appears in the transplanted kidney but in a very small proportion of tubules, often less than one in 300 tubule cross sections. Where the necrosis does occur it tends to affect the entire tubule cross section, as in the center of this field [3].

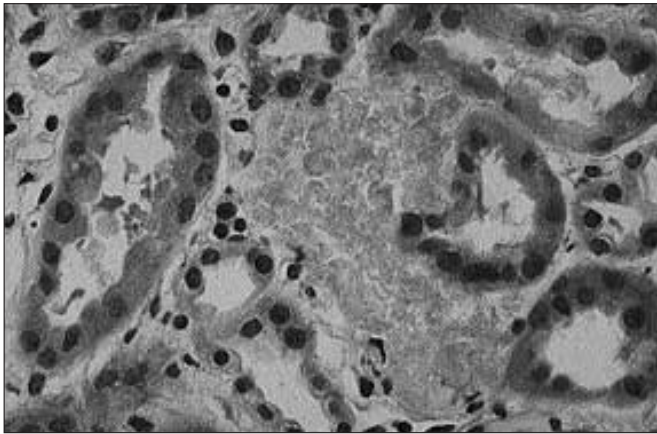


FIGURE 10-11 (see Color Plate)

A completely necrotic tubule in the center of the picture in a case of acute tubular necrosis (ATN) in an allograft. The tubule is difficult to identify because, in contrast to the appearance in native kidney ATN, no residual tubular cells survive; the epithelium is 100% necrotic.

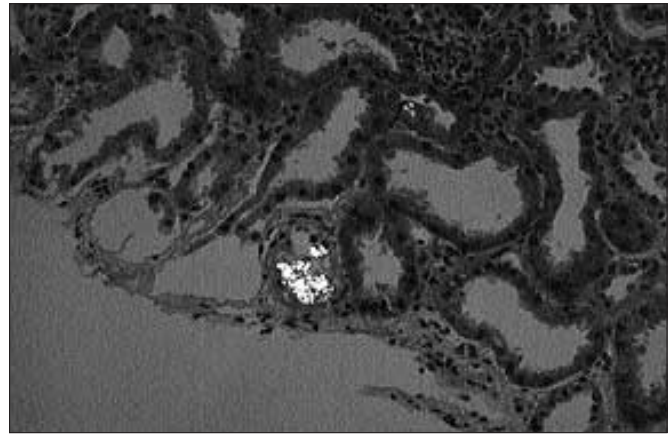


FIGURE 10-12 (see Color Plate)

Calcium oxalate crystals seen under polarized light. These are very characteristic of transplant acute tubular necrosis (ATN), probably because they relate to some degree to the duration of uremia, which is often much longer in transplant ATN (counting the period of uremia before transplantation) than in native ATN. With prolonged uremia elevation of plasma oxalate is greater and more persistent and consequently tissue deposition is greater [4].




FIGURE 10-13

Calcium oxalate crystals seen by electron microscopy in transplant acute tubular necrosis.

FEATURES OF TRANSPLANT ACUTE TUBULAR NECROSIS (ATN) WHICH DIFFERENTIATE IT FROM NATIVE KIDNEY ATN

1. Apparently intact proximal tubular brush border
2. Occasional foci of necrosis of entire tubular cross sections
3. More extensive calcium oxalate deposition
4. Significantly fewer tubular casts
5. Significantly more interstitial inflammation
6. Less cell-to-cell variation in size and shape ("tubular cell unrest")

FIGURE 10-14

Features of transplant acute tubular necrosis that differentiate it from the same condition in native kidney [3].

Cyclosporine Toxicity

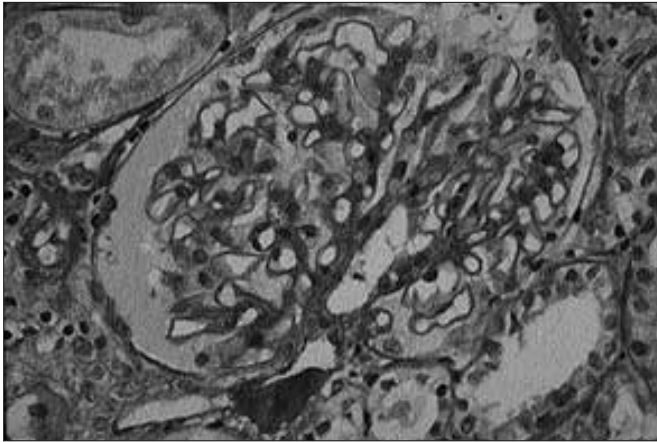


FIGURE 10-15

Cyclosporine nephrotoxicity with new-onset hyaline arteriolar thickening in the renin-producing portion of the afferent arteriole [5]. This lesion can be highly variable in extent and severity from section to section of the biopsy specimen, and it represents one of the strong arguments for examining multiple sections. The lesion is reversible if cyclosporine levels are reduced. Tacrolimus (FK506) produces an identical picture.

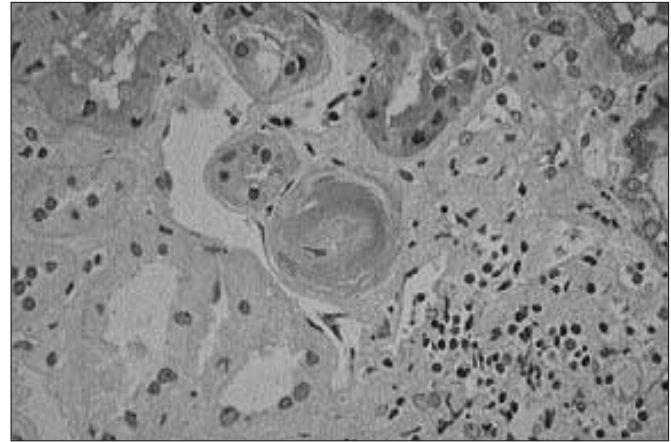


FIGURE 10-16 (see Color Plate)

Bland hyaline arteriolar thickening of donor origin in a renal allograft recipient never treated with cyclosporine. This phenomenon provides a strong argument for doing implantation biopsies; otherwise, donor changes can be mistaken for cyclosporine toxicity.

Posttransplant Lymphoproliferative Disorder

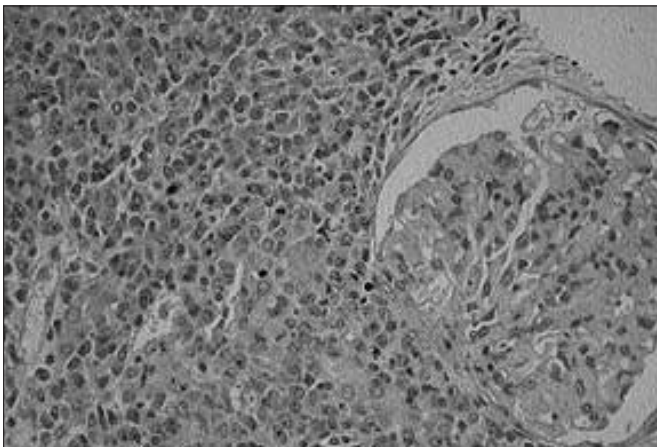


FIGURE 10-17

Posttransplant lymphoproliferative disorder (PTLD). The least satisfying facet of the 1997 Fourth Banff Conference on Allograft Pathology was the continued lack of good tools for the renal pathologist trying to distinguish the more subtle forms of PTLD from rejection. PTLD is rare, but, if misdiagnosed and treated with increased (rather than decreased) immunosuppression, it can quickly lead to death. The fact that both rejection and PTLD can occur simultaneously makes the challenge even greater [6]. It is hoped that newer techniques will make the diagnosis of this important condition more accurate in the future [7–9]. This figure shows an expansile plasmacytic infiltrate in a case of PTLD. However, most cases of PTLD are the result of Epstein-Barr virus-induced lymphoid proliferation.

Subclinical Rejection

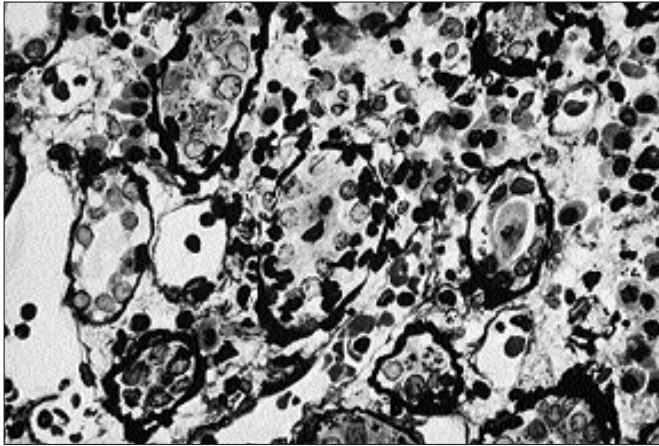


FIGURE 10-18 (see Color Plate)

Subclinical rejection. Subclinical rejection characterized by moderate to severe tubulitis may be found in as many as 35% of normally functioning grafts. Far from representing false-positive readings, such findings now appear to represent bona fide smoldering rejection that, if left untreated, is associated with increased incidence of chronic renal functional impairment and graft loss [10,11]. The important debate for the future is when to perform protocol biopsies to identify subclinical rejection and how best to treat it. This picture shows severe tubulitis in a normally functioning graft 15 months after transplantation. In the tubule in the center are 30 lymphocytes (versus 14 tubule cells). A year and a half later the patient developed renal functional impairment.

Thrombotic Microangiopathy

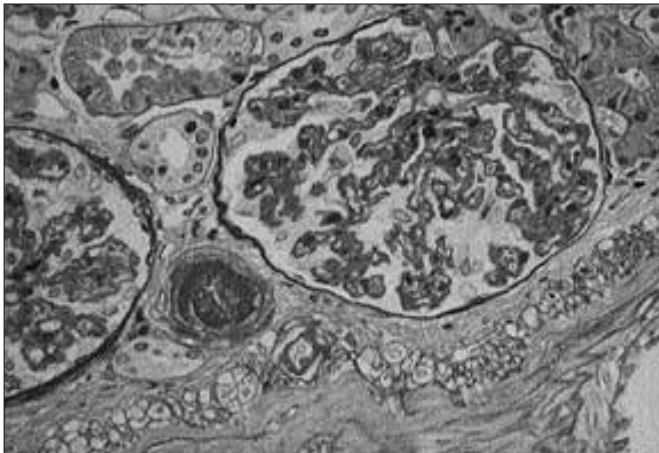


FIGURE 10-19

Thrombotic microangiopathy in renal allografts. A host of different conditions and influences can lead to arteriolar and capillary thrombosis in renal allografts and these are as various as the first dose reaction to OKT3, HIV infection, episodes of cyclosporine toxicity, and antibody-mediated rejection [2, 12, 13]. It is hoped that further study will allow for more accurate diagnosis in patients manifesting this lesion. The figure shows arteriolar thrombosis and ischemic capillary collapse in a case of transplant thrombotic microangiopathy.

Peritubular Capillary Basement Membrane Changes in Chronic Rejection

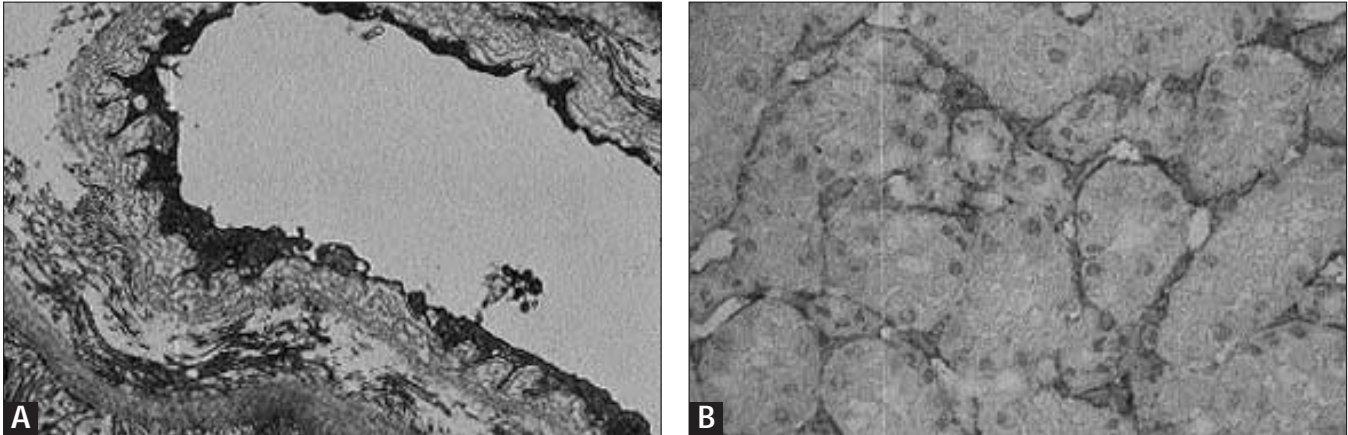


FIGURE 10-20 (see Color Plate)

Peritubular capillary basement membrane ultrastructural changes, **A**, and staining for VCAM-1 as specific markers for chronic rejection, **B** [14–16]. Splitting and multilayering of peritubular capillary basement membranes by electron microscopy holds promise as a relatively specific marker for chronic rejection [14,15]. VCAM-1 staining by immunohistology in these same structures may also be

of diagnostic utility [16]. Ongoing studies of large numbers of patients using these parameters will test the value of these parameters which may eventually be added to the Banff classification. **A**, Multilayering of peritubular capillary basement membrane in a case of chronic rejection; **B**, shows staining of peritubular capillaries for VCAM-1 by immunoperoxidase in chronic rejection.

References

1. Solez K, Axelsen RA, Benediktsson H, *et al.*: International standardization of criteria for the histologic diagnosis of renal allograft rejection: The Banff working classification of kidney transplant pathology. *Kidney Int* 1993, 44:411–422.
2. Trpkov K, Campbell P, Pazderka F, *et al.*: Pathologic features of acute renal allograft rejection associated with donor-specific antibody, analysis using the Banff grading schema. *Transplantation* 1996, 61(11):1586–1592.
3. Solez K, Racusen LC, Marcussen N, *et al.*: Morphology of ischemic acute renal failure, normal function, and cyclosporine toxicity in cyclosporine-treated renal allograft recipients. *Kidney Int* 1993, 43(5):1058–1067.
4. Salyer WR, Keren D: Oxalosis as a complication of chronic renal failure. *Kidney Int* 1973, 4(1):61–66.
5. Strom EH, Epper R, Mihatsch MJ: Cyclosporin-associated arteriopathy: The renin producing vascular smooth muscle cells are more sensitive to cyclosporin toxicity. *Clin Nephrol* 1995, 43(4):226–231.
6. Trpkov K, Marcussen N, Rayner D, *et al.*: Kidney allograft with a lymphocytic infiltrate: Acute rejection, post-transplantation lymphoproliferative disorder, neither, or both entities? *Am J Kidney Dis* 1997, 30(3):449–454.
7. Sasaki TM, Pirsch JD, D'Alessandro AM, *et al.*: Increased β 2-microglobulin (B2M) is useful in the detection of post-transplant lymphoproliferative disease (PTLD). *Clin Transplant* 1997, 11(1):29–33.
8. Chetty R, Biddolph S, Kaklamanis L, *et al.*: bcl-2 protein is strongly expressed in post-transplant lymphoproliferative disorders. *J Pathol* 1996, 180(3):254–258.
9. Wood A, Angus B, Kestevan P, *et al.*: Alpha interferon gene deletions in post-transplant lymphoma. *Br J Haematol* 1997, 98(4):1002–1003.
10. Nickerson P, Jeffrey J, McKenna R, *et al.*: Do renal allograft function and histology at 6 months posttransplant predict graft function at 2 years? *Transplant Proc* 1997, 29(6):2589–2590.
11. Rush D: Subclinical rejection. Presentation at Fourth Banff Conference on Allograft Pathology, March 7–12, 1997.
12. Wiener Y, Nakhleh RE, Lee MW, *et al.*: Prognostic factors and early resumption of cyclosporin A in renal allograft recipients with thrombotic microangiopathy and hemolytic uremic syndrome. *Clin Transplant* 1997, 11(3):157–162.
13. Frem GJ, Rennke HG, Sayegh MH: Late renal allograft failure secondary to thrombotic microangiopathy—human immunodeficiency virus nephropathy. *J Am Soc Nephrol* 1994, 4(9):1643–1648.
14. Monga G, Mazzucco G, Messina M, *et al.*: Intertubular capillary changes in kidney allografts: A morphologic investigation on 61 renal specimens. *Mod Pathol* 1992, 5(2):125–130.
15. Mazzucco G, Motta M, Segoloni G, Monga G: Intertubular capillary changes in the cortex and medulla of transplanted kidneys and their relationship with transplant glomerulopathy: An ultrastructural study of 12 transplantectomies. *Ultrastruct Pathol* 1994, 18(6):533–537.
16. Solez K, Racusen LC, Abdulkareem F, *et al.*: Adhesion molecules and rejection of renal allografts. *Kidney Int* 1997, 51(5):1476–1480.